



Assessment of the Hepatoprotective Activity of *Tragopogon graminifolius* DC. Aqueous Extract on CCl₄- Induced Hepatotoxicity in Mice

Mohammad Mahdi Zangeneh^{1,2*} , Akram Zangeneh^{1,2}, Reza Tahvilian³, Rohallah Moradi²

¹Department of Clinical Science, Faculty of Veterinary Medicine, Razi University, Kermanshah, Iran.

²Biotechnology and Medicinal Plants Research Center, Ilam University of Medical Sciences, Ilam, Iran.

³Pharmaceutical Sciences Research Center, Health Institute, Kermanshah University of Medical Sciences, Kermanshah, Iran.

Abstract

Background and objectives: *Tragopogon graminifolius* DC. is widely used in Iranian traditional medicine as a gastro-protective and wound healer agent. In the present study the hepatoprotective property of *T. graminifolius* DC. aqueous extract (TGAE) was investigated against carbon tetrachloride (CCl₄) induced hepatocellular injury in mice. **Methods:** Fifty male mice were divided into five groups (n=10). Group 1 (control) received 1 ml/kg olive oil intraperitoneally (i.p.) and distilled water orally; Group 2 (untreated) received CCl₄ (50% in olive oil, 1 ml/kg; i.p.); Groups 3, 4 and 5 received CCl₄ and 30, 90 and 270 mg/kg of TGAE (TGAE30, TGAE90 and TGAE270), respectively. At the end of the 45-day treatment, the mice of all groups were euthanized, then blood and liver samples were collected for biochemical and histological parameters analysis. The data was analyzed by one way variance analysis and Duncan's test using SPSS 21. **Results:** Different doses of TGAE (especially TGAE270) could significantly ($p \leq 0.05$) reduce the raised levels of ALP, AST, ALT, Cholesterol, LDL and increased HDL, SOD, CAT as compared to the untreated group. The weight and volume of the hepatic structures decreased significantly ($p \leq 0.05$) in several doses of TGAE (especially TGAE270) when compared to the untreated group. **Conclusion:** The results of the present study showed that under the present experimental conditions, TGAE indicated hepatoprotective abilities against CCl₄ induced liver damage in mice.

Keywords: aqueous extract; CCl₄; hepatoprotective activity; *Tragopogon graminifolius*

Citation: Zangeneh MM, Zangeneh A, Tahvilian R, Moradi R. Assessment of the hepatoprotective activity of *Tragopogon graminifolius* DC. aqueous extract on CCl₄-induced hepatotoxicity in mice. Res J Pharmacogn. 2019; 6(4): 61-69.

Introduction

The liver plays an important and necessary role in human metabolism and detoxification of exogenous and endogenous chemicals [1]. Liver dysfunctions or injuries have been recognized as serious health problems. Especially chronic and acute liver injuries resulted from the exposure to toxic virus, drugs and chemicals infiltration from infection or ingestion, have gained more attention in recent years [2].

Carbon tetrachloride (CCl₄) is a toxic substance for most organs of the body such as the liver,

heart, kidneys, testes, brain and blood. Furthermore, several documented case studies have established that CCl₄ produces hepatic disease with a changed antioxidant status in humans and animals [3]. Findings from the screening of different ethno medicinal plants have described their antioxidant activity and indicated that they could protect liver against CCl₄ by increasing the levels of antioxidant enzymes [4].

Medicinal plants are popular remedies used by

* Corresponding author: Zangeneh.mahdi@stu.razi.ac.ir

most people [5-8]. The impression of ethno medicinal plants in prevention, control and treatment of diseases is irrecusably [9-13].

Tragopogon graminifolius DC. ("Sheng" in Kurdish) grows widely in the western parts of Iran and is economically important as an ethno medicinal plant. *Tragopogon graminifolius* is used to treat poisoning and as astringent and bleeding inhibitor, aseptic property, wound healer and gastro-protector in Iranian traditional medicine [14]. It is also used for healing digestive bleeding and pulmonary and digestive ulcer. This plant was presented as one of the most useful plants for digestive ulcer in traditional medicine [15].

Active constituents of *Tragopogon* genus are flavonoids which consist of vitexin, vicenin-1 and 2, swertisin, quercetin, orientin, luteolin, lucenin, isovitexin, isoorientin and apigenin [16,17]. Some *Tragopogon* species have triterpene saponins like tragopogonosides A-I and vitamin C, K and E, were recognized from some *Tragopogon* species [18,19].

In the present study, we investigated the ameliorative property of the *T. graminifolius* aqueous extract (TGAE) by studying the microscopic structural changes in mice liver after CCl₄-induced hepatotoxicity using new design-based stereological methods. Hepatic functions were also investigated by examining biochemical parameters.

Material and Methods

Ethical considerations

The animal procedures were approved by standards of Payame Noor University of Kermanshah (No. 01/Z/G 1395/12/01) on Humane Care and Use of Laboratory Animals, in accordance with the Research Ethics Committee of the Ministry of Health and Medical Education in Iran (adopted on April 17, 2006), based on the Helsinki Protocol (Helsinki, Finland, 1975). Animal studies were approved by Local Research Ethics Committee of Razi University, Kermanshah, Iran with the ethical code of 397-3-001.

Plant collection and extraction

Tragopogon graminifolius was collected in May 2017 from Kermanshah province (in west of Iran). The plant was identified by the herbarium of the Research Center of the Agriculture Faculty, Tehran University (Herbarium number 43603).

The leaves of the plant were shade-dried for one week. The dried aerial parts of the plant were grinded, and about 200 g of the obtained powder was extracted with 1000 mL distilled water for 2 hours at 40°C by continuous shaking. The extract was left for 24 hours at room temperature; it was then filtered through Whatman paper no. 2. In rotary evaporator (Panchun Scientific Co., Kaohsiung, Taiwan), the extract was concentrated and lyophilized afterward [13].

Animals

Male Balb/c mice weighing between 38-40 g were procured from laboratory animal center of Kermanshah University of Medical Sciences. The animals were housed in an air-conditioned room (22±2 °C) with 12 h light/dark cycle and has free access to standard pellet diet and water *ad libitum* conditions during the study.

Experimental design

In the present study, a total of 50 mice were used. The mice were divided into five groups of ten mice each. Group I served as control, received 1mL/kg olive oil intraperitoneally and 0.5 mL distilled water through gavage. Group II served as untreated group, received 1 ml/kg CCl₄ (CAS Number 56-23-5, Merck company, Germany) mixed with olive oil in the ratio of 1:1, intraperitoneally and 0.5 mL distilled water orally. Group III, IV and V received CCl₄ mixed with olive oil in the ratio of 1:1 intraperitoneally and 30, 90 and 270 mg/kg of TGAE (TGAE30, TGAE90 and TGAE270) through gavage, respectively. The animals treated twice a week for 45 consecutive days [4,20].

At the end of the 45-day treatment, the animals of all groups were euthanized by ketamine HCl (40 mg/kg). Then blood samples were drawn from mice heart and inserted in serum tubes for determination of ALP (Alkaline phosphatase), AST (Aspartate aminotransferase), ALT (Alanine aminotransferase), cholesterol, LDL (Low-density lipoprotein) and HDL (High-density lipoprotein). All above parameters were measured by available commercial kits (Pars Azmun CO, Iran) according to its procedures.

Also the capacity of antioxidant enzymes was assessed by determining the activity of SOD and CAT in whole liver of each group (n=5) using the procedures reported by Abei (1974) and Martin et al (1987) [21,22].

Histological study

The liver of each group (n=5) was dissected out and washed with ice cold saline to remove blood. The livers weighed and immersed in 10% neutral buffered formaldehyde. Liver volume is obtained from liver dipping method in water. After 72h fixation, the livers were cut using orientator method. Totally, 7–10 slabs were collected from each liver. The slabs were embedded in paraffin and sections (5 µm thicknesses) were prepared and stained by hematoxyline and eosin stain.

Volume density of liver structures including hepatocytes, sinusoids, central veins, portal veins, hepatic arteries, and bile ducts estimated with point counting rule briefly as follow: one section from each liver was used. The images of microscopical fields from each section were projected on point probe (frame 15cm×15cm) by video projector via microscope equipped with a camera (Dinocapture ver.5, dino-lit.com 30.5 mm) attached to the computer.

At total magnification of 2000×, points that hit desired structures were counted and volume density was estimated using following formula:

$$Vv = P_{\text{structure}} / P_{\text{reference}}$$

Where $P_{\text{structure}}$ and $P_{\text{reference}}$ were the number of points falling on the structure's profile and on the reference space, respectively. 10-14 microscopic fields were examined in each liver. The absolute volume of the structures was estimated by multiplying the fractional volume by the final volume of the liver to prevent the reference trap [23,24].

Statistical analysis

Data expressed as mean ± SD and were analyzed by one way ANOVA and Duncan's test. $P \leq 0.05$ was considered significant.

Results and Discussion

In this study, body weight reduced significantly ($p \leq 0.05$) in untreated mice compared to the control ones (Figure 1). Administration of TGAE at all doses could significantly ($p \leq 0.05$) enhance body weight in comparison with the untreated group. There aren't difference significant among TGAE30, TGAE90, TGAE270 and control groups. Administration of TGAE at all doses could significantly ($p \leq 0.05$) ameliorate the liver weight and volume compared to the untreated group (Figures 2,3).

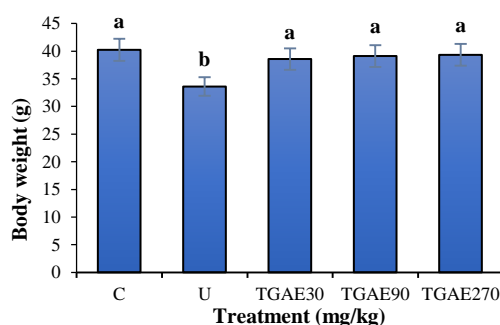


Figure 1. Weights of body in all experimental groups. C: control group; U: untreated group; TGAE30, TGAE90 and TGAE270: treated groups with 30, 90 and 270 mg/kg of *Tragopogon graminifolius* aqueous extract; non-identical letters indicate a significant difference between the groups ($p \leq 0.05$).

The volume hepatocytes, central veins, sinusoids, portal veins, hepatic arteries and bile ducts were increased significantly ($p \leq 0.05$) in untreated mice compared to the control ones (Figures 4-7). Administration of TGAE at all doses could significantly ($p \leq 0.05$) decrease the volume of the above structures in comparison with the untreated group. Also gavage of TGAE30 could significantly ($p \leq 0.05$) reduce volume of hepatic arteries similar to the control group. There were no significant differences in volumes of portal veins, hepatic arteries and bile ducts ($p \leq 0.05$) between TGAE90 and control groups. TGAE270 could significantly ($p \leq 0.05$) decrease volumes of sinusoids, portal veins, hepatic arteries and bile ducts similar to the control group.

The estimated values of the liver enzymes are presented in figures 8-10. CCl_4 - induced toxicity enhanced ALP, AST, ALT, cholesterol, LDL and decreased HDL, SOD and CAT significantly ($p \leq 0.05$) as compared to the control group.

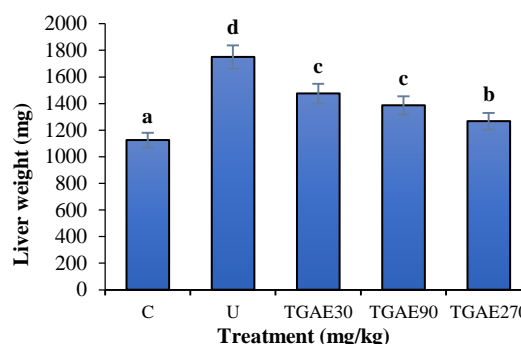


Figure 2. Weights of liver in all experimental groups C: control group; U: untreated group TGAE30, TGAE90 and TGAE270: treated groups with 30, 90 and 270 mg/kg of *Tragopogon graminifolius* aqueous extract; non-identical letters indicate a significant difference between the groups ($p \leq 0.05$).

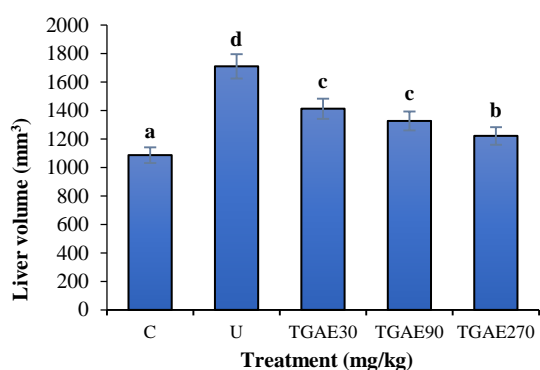


Figure 3. Volumes of liver in all of the experimental groups. C: control group; U: untreated group; TGAE30, TGAE90 and TGAE270: treated groups with 30, 90 and 270 mg/kg of *Tragopogon graminifolius* aqueous extract; non-identical letters indicate a significant difference between the groups ($p \leq 0.05$).

Different doses of TGAE could significantly ($p \leq 0.05$) reduce the raised levels ALP, AST, ALT, cholesterol, LDL and increase HDL, SOD and CAT significantly ($p \leq 0.05$) as compared to the untreated group. There aren't significant differences between TGAE90 and control groups in LDL and HDL levels ($p \leq 0.05$). TGAE270 could significantly ($p \leq 0.05$) regulate AST, cholesterol, LDL, HDL and CAT similar to the control group.

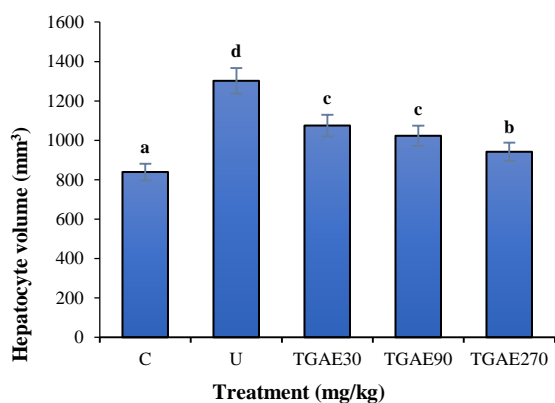


Figure 4. Volume of hepatocytes in all of the experimental groups. C: control group; U: untreated group; TGAE30, TGAE90 and TGAE270: treated groups with 30, 90 and 270 mg/kg of *Tragopogon graminifolius* aqueous extract; non-identical letters indicate a significant difference between the groups ($p \leq 0.05$).

The remedial benefits of herbal medicine have been realized for centuries on the basis of clinical practice and experience. They have the immense effect for the control and treatment of every disease such as hepatotoxicity [4,11]. A list of medicinal plants that are used for their

hepatoprotective property including *Acacia nilotica* Linn, *Abelmoschus manihot*, *Moringa oleifera* Lam, *Daucus carota*, *Garcinia indica*, *Feijoa sellowiana*, *Ficus religiosa*, *Melastoma malabathricum* L, *Terminalia paniculata*, *Feronia limonia*, *Cissus quadrangularis*, *Zingiber officinale* Roscoe, *Astragalus kahiricus*, *Vitex glabrata* and *Fagonia schweinfurthii* [25].

In this experimental study the hepatoprotective property of TGAE at several doses was determined in CCl₄-induced hepatotoxicity in mice model. But, to our knowledge, this is the first time TGAE with these doses has been used from experimentally induced hepatotoxicity in mice.

The extension of hepatic damages is evaluated by the elevated serum levels of cytoplasmic enzymes as well as by histological examination [26,27]. The enhanced serum parameters levels such as ALP, AST, ALT, cholesterol and LDL have been ascribed to the damaged structural integrity of the liver [26,27]. Administration of CCl₄ produce liver damage in mice as manifested by the rise in serum parameters levels of ALP, AST and ALT [4, 27]. Also in previous study on the mechanism of CCl₄-induced hepatotoxicity has shown that endogenous antioxidants play a crucial role in detoxifying the reactive toxic derivatives of CCl₄ and that liver necrosis begins when antioxidant stores are markedly depleted [26]. In this study, the increased levels of ALP, AST, ALT, cholesterol and LDL were significantly decreased following administration of different doses of TGAE (especially 270 mg/kg) and these changes can be related to the antioxidant compounds present in the plant. Antioxidant property of *Tragopogon* genus aerial parts has been reported *in vitro* [20]. Flavonoids including luteolin, apigenin, quercetin and vitexin are the antioxidant compounds of *Tragopogon* genus [28,29]. These constituents have demonstrated protective effect against HCl/ethanol-induced gastric ulcer and healing property against acetic acid-induced chronic gastric ulcer with inhibition of gastric tissue lipid peroxidation [30]. In other study revealed that quercetin-3-O- α -D-glucuronopyranoside, a compounds of *Tragopogon* genus, protected gastric mucus against indomethacin-induced ulcer by rising gastric mucus secretion, decreasing of myeloperoxidase (MPO) effect and free radical production, preventing the expression of intercellular adhesion molecule protein and

down regulation of the pro-inflammatory cytokines [31].

In the present study, the *in vivo* data indicated that animals treated with CCl_4 exhibited a substantial ($p \leq 0.05$) reduce in the levels of liver antioxidant enzymes such as SOD and CAT compared to the control animals. TGAE at all doses (especially 270 mg/kg) enhanced level of

SOD and CAT with ameliorating of liver function. A study demonstrated similar hepatoprotection against CCl_4 while using silymarin (a reference drug) at a concentration of 200 mg/kg, an effect analogous to the 250 mg/kg dose of *Tragopogon* genus [32].

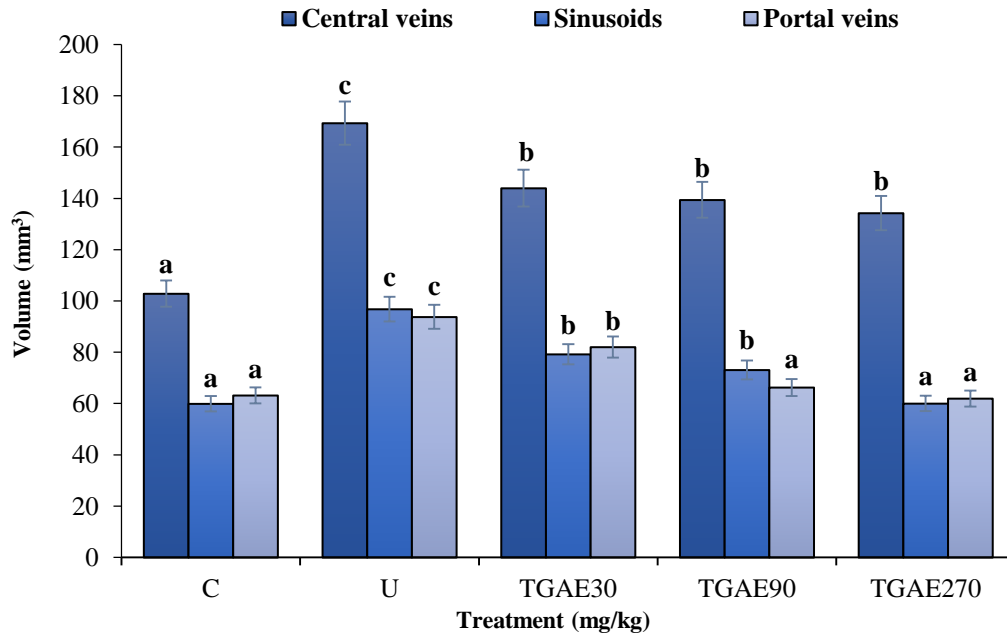


Figure 5. Volume of central veins, sinusoids and portal veins in all of the experimental groups. C: control group; U: untreated group; TGAE30, TGAE90 and TGAE270: treated groups with 30, 90 and 270 mg/kg of *Tragopogon graminifolius* aqueous extract; non-identical letters indicate a significant difference between the groups ($p \leq 0.05$).

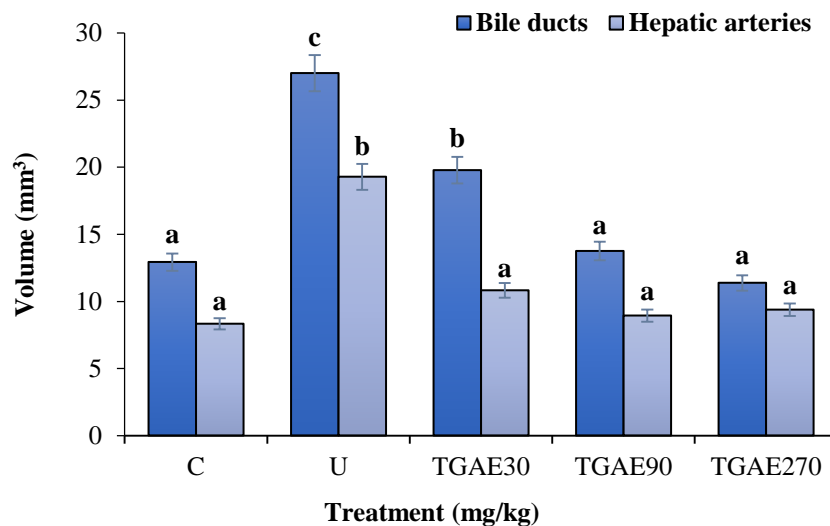


Figure 6. Volume of hepatic arteries and bile ducts in all of the experimental groups. C: control group; U: untreated group; TGAE30, TGAE90 and TGAE270: treated groups with 30, 90 and 270 mg/kg of *Tragopogon graminifolius* aqueous extract; non-identical letters indicate a significant difference between the groups ($p \leq 0.05$).

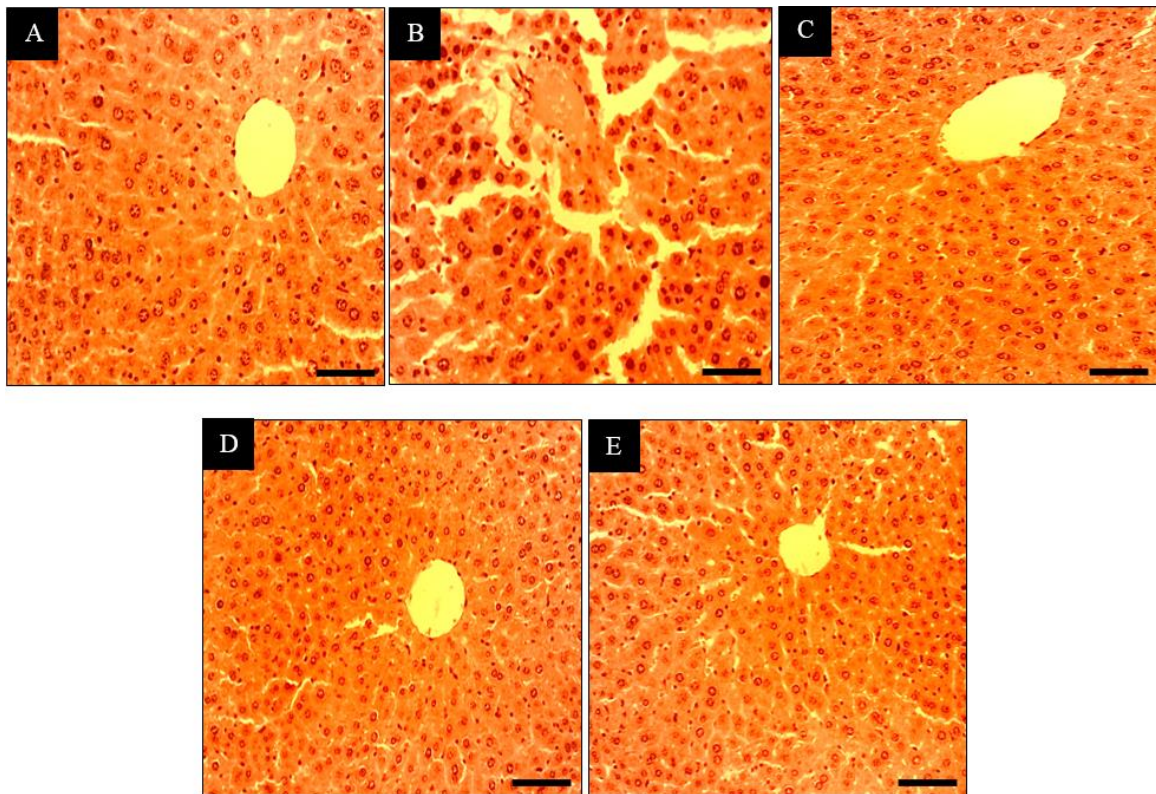


Figure 7. Longitudinal sections of liver (scale bar for 150 μm) with Hematoxylin-Eosin staining. A: control group, B: untreated group; C, D and E: treated groups with 30, 90 and 270 mg/kg of *Tragopogon graminifolius* aqueous extract

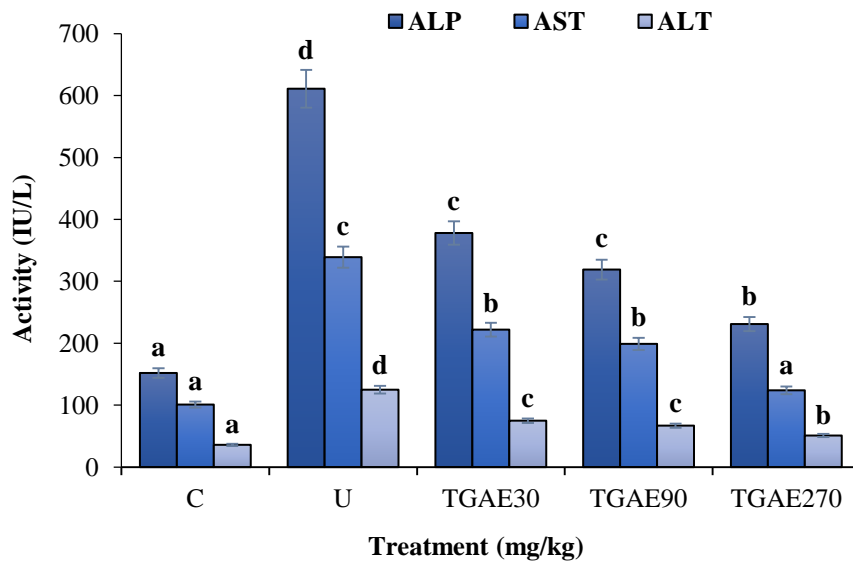


Figure 8. ALP, AST and ALT levels in all of the experimental groups. C: control group; U: untreated group; TGAE30, TGAE90 and TGAE270: treated groups with 30, 90 and 270 mg/kg of *Tragopogon graminifolius* aqueous extract; non-identical letters indicate a significant difference between the groups ($p \leq 0.05$).

Other results of this study demonstrated that the liver of CCl_4 -treated mice indicated a considerable hypertrophy which leads to enhance in weight and volume of the hepatic structures.

The pathogenesis of liver hypertrophy can be ascribed to the overproduction of oxygen-free radicals following administration of toxins such as CCl_4 , which is expressed in response to

cytokines [33]. These changes were alleviated significantly in all doses of TGAE (especially 270 mg/kg). Thus, these results offered that TGAE could be used to ameliorate hepatic structural changes due to CCl₄-induced toxicity. Agree with this experiment, in a study revealed that ethno medicinal plant reduce weight and volume of hepatocytes, central veins, sinusoids, portal veins, hepatic arteries and bile ducts in CCl₄-induced hepatotoxicity in mice [4].

The hepatoprotection by TGAE may be due to antioxidant property of the phytochemicals present in TGAE which decrease the oxidative stress imposed by CCl₄ and other like anti-inflammatory and analgesic properties preventing the inflammatory hepatic damage [3,34].

We conclude that the *T. graminifolius* collected from Kermanshah province (in west of Iran), has hepatoprotective effect against CCl₄-induced hepatotoxicity in mice. Further studies are highly recommended to identify the active components of the extract and molecular mechanisms responsible for this hepatoprotection.

Acknowledgments

The authors would like to thank the Razi University for the financial support.

Author contributions

Mohammad Mahdi Zangeneh prepared the manuscript; Mohammad Mahdi Zangeneh and Akram Zangeneh performed the biochemical analysis; Mohammad Mahdi Zangeneh designed and performed the stereological plan; Reza Tahvilian and Rohallah Moradi contributed in the statistical analysis; Akram Zangeneh was involved in animal handling and treatments; Reza Tahvilian and Rohallah Moradi prepared the plant extract

Declaration of interest

The authors declare that there is no conflict of interest. The authors alone are responsible for the content of the paper.

References

- [1] Alter MJ. Epidemiology of viral hepatitis and HIV coinfection. *J Hepatol.* 2006; 44(1): 6-9.
- [2] Lee CP, Shih PH, Hsu CL, Yen GC. Hepatoprotection of tea seed oil (*Camellia oleifera* Abel.) against CCl₄-induced oxidative damage in rats. *Food Chem Toxicol.* 2007; 45(6): 888-895.
- [3] Alia M, Horcajo C, Bravo L, Goya L. Effect of grape antioxidant dietary fiber on the total antioxidant capacity and the activity of liver antioxidant enzymes in rats. *Nutr Res.* 2003; 23(9): 1251-1267.
- [4] Goodarzi N, Zangeneh MM, Zangeneh A, Najafi F, Tahvilian R. Protective effects of ethanolic extract of *Allium Saralicum* R.M. Fritsch on CCl₄- induced hepatotoxicity in mice. *J Rafsanjan Univ Med Sci.* 2017; 16(3): 227-238.
- [5] Sherkatolabbasieh H, Hagh-Nazari L, Shafiezadeh S, Goodarzi N, Zangeneh MM, Zangeneh A. Ameliorative effect of the ethanolic extract of *Allium saralicum* R.M. Fritsch on CCl₄-induced nephrotoxicity in mice: a stereological examination. *Arch Biol Sci.* 2017; 69(3): 535-543.
- [6] Faramarzi E, Zangeneh MM, Zangeneh A, Moradi R. Effect of *Cinnamomum zelanicum* oil on hyponeophagia anxiety test in Balb C male mice. *Online J Vet Res.* 2017; 21(2): 77-80.
- [7] Foroughi A, Pournaghi P, Najafi F, Zangeneh A, Zangeneh MM, Moradi R. Antibacterial effect and phytochemical screening of essential oil of *Pimpinella anisum* against *Escherichia coli* O157:H7 and *Staphylococcus aureus*. *Int J Curr Med Pharm Res.* 2016; 7(6): 367-371.
- [8] Tahvilian R, Moradi R, Zhaleh H, Zangeneh MM, Zangeneh A, Yazdani H, Hajialiani M. Chemical composition and screening of antibacterial activity of essential oil of *Pistacia khinjuk* against two selected pathogenic bacteria. *Ann Trop Med Public Health.* 2017; 10(5): 1159-1164.
- [9] Ghashghaii A, Hashemnia M, Nikousefat Z, Zangeneh MM, Zangeneh A. Wound healing potential of methanolic extract of *Scrophularia striata* in rats. *Pharm Sci.* 2017; 23(4): 256-263.
- [10] Hagh-Nazari L, Goodarzi N, Zangeneh MM, Zangeneh A, Tahvilian R, Moradi R. Stereological study of kidney in streptozotocin-induced diabetic mice treated with ethanolic extract of *Stevia rebaudiana* (bitter fraction). *Comp Clin Pathol.* 2017; 26(2): 455-463.
- [11] Najafi F, Goodarzi N, Zangeneh MM, Zangeneh A, Hagh-Nazari L. Antidiabetic and hepatoprotective effects of bitter fraction of *Stevia rebaudiana* alcoholic extract on

- streptozotocin-induced diabetic male mice. *J Rafsanjan Univ Med Sci.* 2017; 16(6): 493-504.
- [12] Zangeneh MM, Goodarzi N, Zangeneh A, Tahvilian R, Najafi F. Amelioration of renal structural changes in STZ-induced diabetic mice with ethanolic extract of *Allium saralicum* R.M. Fritsch. *Comp Clin Pathol.* 2018; 27(4): 861-867.
- [13] Musabayane CT. The effects of medicinal plants on renal function and blood pressure in diabetes mellitus. *Cardiovasc J Afr.* 2012; 23(8): 462-468.
- [14] Farzaei MH, Khazaei M, Abbasabadei Z, Feyzmahdavi M, Mohseni GR. Protective effect of *Tragopogon graminifolius* DC. against ethanol induced gastric ulcer. *Iran Red Crescent Med J.* 2013; 15(9): 813-816.
- [15] Farzaei MH, Ghasemi-Niri SF, Abdolghafari AH, Baeeri M, Khanavi M, Navaei-Nigjeh M, Abdollahi M, Rahim R. Biochemical and histopathological evidence on the beneficial effects of *Tragopogon graminifolius* in TNBS-induced colitis. *Pharm Biol.* 2015; 53(3): 429-436.
- [16] Kroschewsky JR, Mabry TJ, Markham KR, Alston RE. Flavonoids from the genus *Tragopogon* (compositae). *Phytochemistry.* 1969; 8(8): 1495-1498.
- [17] Sareedenchai V, Ganzera M, Ellmerer EP, Lohwasser U, Zidorn C. Phenolic compounds from *Tragopogon porrifolius* L. *Biochem Syst Ecol.* 2009; 37(3): 234-236.
- [18] Miyase T, Kohsaka H, Ueno A. Tragopogonosides A-I, oleanane saponins from *Tragopogon pratensis*. *Phytochemistry.* 1992; 31(6): 2087-2091.
- [19] Vardavas CI, Majchrzak D, Wagner KH, Elmadfa I, Kafatos A. The antioxidant and phyloquinone content of wildy grown greens in Crete. *Food Chem.* 2006; 99(4): 813-821.
- [20] Mroueh M, Daher C, Sibai ME, Tenkerian C. Antioxidant and hepatoprotective activity of *Tragopogon porrifolius* methanolic extract. *Planta Med.* 2011; 7(12): 72-77.
- [21] Abei H. Catalase. In: Bergmeyer HU, Ed. *Methods of enzymatic analysis.* New York: Academic Press, 1974.
- [22] Martin JP, Dailey M, Sugarman E. Negative and positive assays of superoxide dismutase based on hematoxylin autoxidation. *Arch Biochem Biophys.* 1987; 255(2): 329-336.
- [23] Mandarim-de-Lacerda CA. Stereological tools in biomedical research. *An Acad Bras Cienc.* 2003; 5(4): 469-486.
- [24] Nyengaard JR. Stereologic methods and their application in kidney research. *J Am Soc Nephrol.* 1999; 10(5): 1100-1123.
- [25] Roy A, Bhoumik D, Sahu RK, Dwivedi J. Medicinal plants used in liver protection - a review. *UK J Pharm Biosci.* 2014; 2(1): 23-33.
- [26] Recknagel RO, Glendejr EA, Britton RS. Free radical damage and lipid peroxidation. In: Meeks RG, Ed. *Hepatotoxicology.* Florida: CRC Press, 1991.
- [27] Zangar RC, Benson JM, Burnett VL, Springer DL. Cytochrome P4502E1 is the primary enzyme responsible for low-dose carbon tetrachloride metabolism in human liver microsomes. *Chem Biol Interact.* 2000; 125(3): 233-243.
- [28] Belzer NF, Ownbey M. Chromatographic comparison of *Tragopogon* species and hybrids. *Am J Bot.* 1971; 58(9): 791-802.
- [29] Mojarab M, Khan-Mohammadi A, Hosseinzadeh L, Siavash-Haghighi ZM. Antioxidant activity and safety assessment of *Tragopogon bupthalmoides* hydroethanolic extract: acute and subchronic toxicities. *Res Pharm Sci.* 2014; 9(5): 359-366.
- [30] Suzuki S, Ishihara M, Segami T, Ito M. Anti-ulcer effects of antioxidants, quercetin, α -tocopherol, nifedipine and tetracycline in rats. *Jpn J Pharmacol.* 1998; 78(4): 435-441.
- [31] Yan XM, Joo MJ, Lim JC, Whang WK, Sim SS, Im C, Kim HR, Lee SY, Kim IK, Sohn UD. The effect of quercetin-3-O- β -D-glucuronopyranoside on indomethacin-induced gastric damage in rats via induction of mucus secretion and down-regulation of ICAM-1 expression. *Arch Pharm Res.* 2011; 34(9): 1527-1534.
- [32] Jadhav VB, Thakare VN, Suralkar AA, Deshpande AD, Naik SR. Hepatoprotective activity of *Luffa acutangula* against CCl₄ and rifampicin induced liver toxicity in rats: a biochemical and histopathological evaluation. *Ind J Exp Biol.* 2010; 48(4): 822-829.
- [33] Vakati K, Rahman H, Eswaraiyah MC, Dutta AM. Evaluation of hepatoprotective activity of ethanolic extract of *Aquilaria agallocha* leaves (EEAA) against CCl₄ induced hepatic damage in rat. *Sch J App Med Sci.* 2013; 1(1): 9-12.

- [34] Farzaei MH, Khanavi M, Moghaddam G, Dolatshahi F, Rahimi R, Shams-Ardekani MR, Amin G, Hajimahmoodi M. Standardization of *Tragopogon graminifolius* DC. extract based on phenolic compounds and antioxidant activity. *J Chem.* 2014; Article ID 425965.

Abbreviations

ALP: alkaline phosphatase; AST: aspartate aminotransferase; ALT: alanine aminotransferase; LDL: low-density lipoprotein; HDL: high-density lipoprotein; SOD: superoxide dismutase; CAT: catalase