



Protective Effects of Curcumin on the Structural Parameters of Seminiferous Tubules and Leydig Cells in Methandienone Treated Mice

Omid Baharan, Nader Goodarzi* 

Department of Basic and Pathobiological Sciences, Faculty of Veterinary Medicine, Razi Universtiy, Kermanshah, Iran.

Abstract

Background and objectives: Although anabolic androgenic steroids (AAS) use has become more prominent in bodybuilders and professional athletes, their consumption is nowadays a problem that involves a wider population. Methandienone or dianabol is an anabolic androgenic steroid which is used by athletes for fitness. This study was conducted to investigate, the likely protective effects of curcumin on the structural parameters of the testis in dianabol treated mice. **Methods:** A total of 35 male mice were divided into five groups, each containing seven mice. The control group received 0.2 mL distilled water; the second group received 20 mg/kg/day dianabol; third, fourth, and fifth groups received dianabol plus 50, 100, and 200 mg/kg/day of curcumin, respectively. All administrations were done by gavages for 56 days. On the last day, the left testes were examined using stereological methods. The volume of testis and seminiferous tubules, interstitial tissue, and diameter, length and germinal epithelium height of the tubules as well as the number of Leydig cells were estimated. **Results:** The obtained results showed that the weight and volume of the testis as well as volume of the seminiferous tubules and interstitial tissue, length, diameter and epithelium height of the tubules decreased significantly ($p < 0.05$) after dianabol administration compared to the negative control group. Oral administration of curcumin at doses 100 and 200 mg/kg, could significantly improve all the measured parameters toward the normal levels. **Conclusion:** It seems that curcumin due to its anti-oxidant and anti-inflammatory properties can inhibit testis volume reduction and hypogonadism following dianabol administration.

Keywords: curcumin; methandienone; mice; stereology; testis

Citation: Baharan O, Goodarzi N. Protective effects of curcumin on the structural parameters of seminiferous tubules and leydig cells in methandienone treated mice. *Res J Pharmacogn.* 2018; 5(4): 33-41.

Introduction

Anabolic androgenic steroids (AAS) were first described in the 1930s [1,2] and since that time were used for treatment of various diseases such as osteoporosis, cachexia, delayed puberty and breast cancer [3]. Synthetic derivatives of testosterone exhibit both androgenic and anabolic (increase muscle mass) effects, but their anabolic function is more pronounced than testosterone itself [4]. Therefore, there is an increasing trend for their utilization by sports and athletes [5]. Contrary to the common public perception that AAS are used primarily by professional athletes

or those in a small sector of society, it has been found that they are much more common [6]. Unfortunately, it has been well established that use of AAS is associated with a series of significant side effects such as hepatotoxicity, cardiotoxicity, polycythemia, dyslipidemia and testicular toxicity. AAS-induced testicular toxicity can be apparent as testicular atrophy or hypogonadism and infertility [7-9]. There was a case report demonstrated that the abuse of AAS could induce persistent gonadal failures and infertility, as a result, the side effects of anabolic

* Corresponding author: n.goodarzi@razi.ac.ir

steroids can be prolonged and irreversible [10]. AAS can insert their hypogonadotrophic effects by suppressing gonadotropin releasing hormone, luteinizing hormone and follicle-stimulating hormone [6]. Testicular atrophy and fluid retention are two major side effects which have been reported following AAS-induced hypogonadism in young men [6,11].

Curcumin (with chemical name diferuloyl methane) is the main curcuminoid present in turmeric (*Curcuma longa* L., Zingiberaceae) for the first time at 1815 AD and is responsible for its yellow color [12]. Turmeric is widely cultivated in some countries including India and China. This plant has a long history as an anti-inflammatory agent for treatment of clogs, jaundice, anorexia and menstrual disorders. Its local application has been suggested for sinusitis, bruise and skin disorders [13]. Many studies have confirmed that curcumin has antioxidant, anti-inflammatory and anti-tumor effects [14]. It exerts these effects by decreasing inflammatory agents such as interleukin IL-1, IL-6 and tumor necrosis factor (TNF)- α . Also, curcumin interrupts the pathway of arachidonic acid metabolism through inhibiting the phosphorylation of phospholipase A₂ (PLA₂), decreasing the expression of cyclooxygenase COX-2 gene and inhibiting the catabolic activity of 5-LOX [15].

Previous studies have revealed that curcumin can protect the testis from oxidative damage induced by cisplatin, sodium arsenite, aflatoxin and metronidazol in laboratory animals [16-19].

The present study has investigated the potential of curcumin to ameliorates testicular toxicity induced by methandienone (17 α -hydroxy-17 α -methylandroster-1,4-dien-3-one, C₂₀H₂₈O₂) commercially known as dianabol (one of the commonly used anabolic androgenic steroids).

Material and Methods

Ethical considerations

All of the experiments were done according to the rules of the Ethics Committees of Razi University, Kermanshah, Iran (approval code: 396-2-015, 2017/03/08).

Chemicals

Dianabol (tab 10 mg, March pharmaceutical Co., Thailand) and curcumin powder (Merck, Germany) were purchased and dissolved in distilled water to prepare desired doses.

Animals and treatments

BALB/c male mice weighing 35-40 g were procured from the Laboratory Animal House of faculty of Veterinary Medicine, Razi University, Kermanshah, Iran. The mice were acclimatized prior to the experiments and were divided into five groups, each including 7 mice. The first group served as control and received 0.2 mL distilled water by gavages. The second group was treated with high dose (20 mg/kg/day) of dianabol. The third, fourth, and fifth groups received high dose (20 mg/kg/day) of dianabol plus 50, 100, and 200 mg/kg/day of curcumin, respectively. The dose of curcumin was selected according to a previous study [15]. All administrations were done by gavages for 56 days (8 consecutive weeks).

Stereological study

The left testis of each mouse was removed and the epididymis was separated. The testes were then weighted and the primary volume was estimated using immersion method [20]. Afterward, the testes were immersed in %10 buffered formalin for one week. In order to estimate reference volume (total volume), the tissue shrinkage was determined first. Estimation of tissue shrinkage and also total length of seminiferous tubules required isotropic uniform random (IUR) sections. This sections were obtained through orientator method [21,22]. The testis was placed on a circle, such that each half of was divided into 10 equal parts. A random number between 0 and 9 was selected. The testis was sectioned into two parts at the direction of the selected number. The cut surface of one part of the testis was then placed parallel to the 0-0 direction of the second circle with 10 unequal divisions. The circle division was done according to the cosine of the angels. Then, another random number was selected and the second cut was done. The cut surface of the other part of the testis was placed vertically on the second circle. Again, a new number and direction was selected and cut. These parts were entirely sectioned into parallel slabs at the direction of the selected numbers.

Overall, 8-10 slabs were collected from each testis. For estimating tissue shrinkage, a circle was punched from a testis slab by a trocar. The diameter of the circular piece of the testis was measured by a micrometer and the area of the circle was estimated, using the usual formula for

calculating the area of a circle. The cut surfaces of all slabs and circular piece were embedded in paraffin, sectioned (5 μm thicknesses) and stained by Hematoxylin and Eosin method. After staining, the area of the circular piece was measured again and volume shrinkage was calculated from the following formula [22]:

$$\text{Volume shrinkage} = 1 - (\text{AA} / \text{AB})^{1.5}$$

Where, AA and AB are diameter of the punched circle after and before tissue processing and staining.

The final volume of the testis was calculated using the following formula:

$$V_{\text{final}} = V_{\text{primary}} \times (1 - \text{volume shrinkage})$$

Volume estimation

All sampled sections were analyzed by using a video microscopy system consisting of a microscope (Olympus CX2, Japan) linked to a video camera (Dinocapture ver.5, dino-lit.com 30.5 mm), a computer and a flat monitor to determine the parameters. The point probe (10 \times 10 cm composed of 25 points) was superimposed upon the images of the tissue sections viewed on the monitor, and volume density (V_v) of seminiferous tubules, germinal epithelium and interstitial tissue were obtained using a point-counting method (figure 1) from following formula [21]:

$$V_v = P_{\text{structure}} / P_{\text{reference}}$$

In this formula $P_{\text{structure}}$ and $P_{\text{reference}}$ were the number of test points falling on the structures profile and on the reference space, respectively. Eight to twelve microscopic fields were examined in each testis.

The absolute volume of the parameters was estimated by multiplying the fractional volume by the final volume of the testis to prevent the reference trap [22,23].

Length estimation

The length density of the seminiferous tubules was estimated using a counting probe (740 \times 740 μm) and the following formula [22,23]:

$$L_v = 2(\sum Q / a(\text{frame}) \times \sum(\text{frame}))$$

Where $\sum Q$ is sum of the structures counted, $a(\text{frame})$ is probe area, 547600 μm^2 and $\sum \text{frame}$ is total number of the counted frames. The

diameter of the tubules was measured perpendicular to the long axis where the tubule was widest (figure2). An average of 100 profiles was counted per testis.

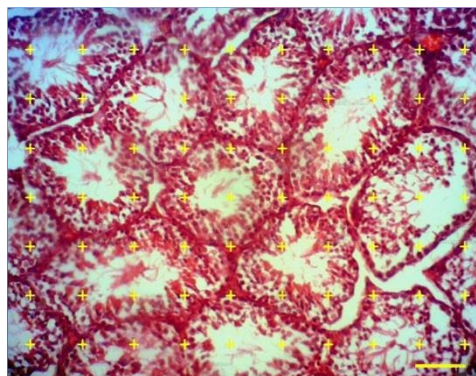


Figure 1. Point counting method: to estimate volume density of the seminiferous tubules and interstitial tissue a point probe was superimposed on the images of the tissue sections. The total number of points hitting each component was divided by the total number of the points hitting the reference space (Hematoxyline and Eosin $\times 100$, scale bar: 50 μm).

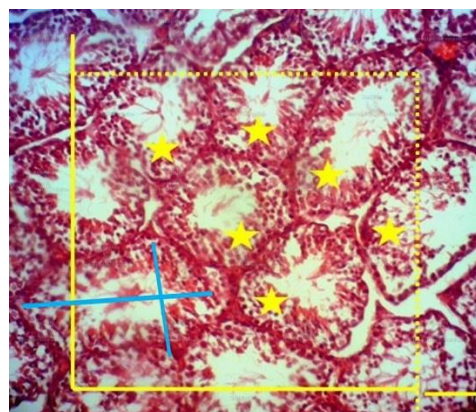


Figure 2. The length density of seminiferous tubules was estimated by superimposing an unbiased counting frame with inclusion (dashed) lines and exclusion (thick) lines on the images of the tissue sections. The tubule profiles completely inside the counting frame or partly inside the counting frame but only touching the inclusion lines were counted (here 6 tubules Hematoxyline and Eosin $\times 100$, scale bar: 50 μm).

Estimation of the germinal epithelium height

The height of the germinal epithelium was estimated using the following formula [22]:

$$H = V_v / S_v$$

In which V_v and S_v were the volume density and surface density of the germinal epithelium, respectively. The volume density of the germinal epithelium was obtained by point counting method and the surface density of the germinal

epithelium was estimated using a linear test probe (figure 3).

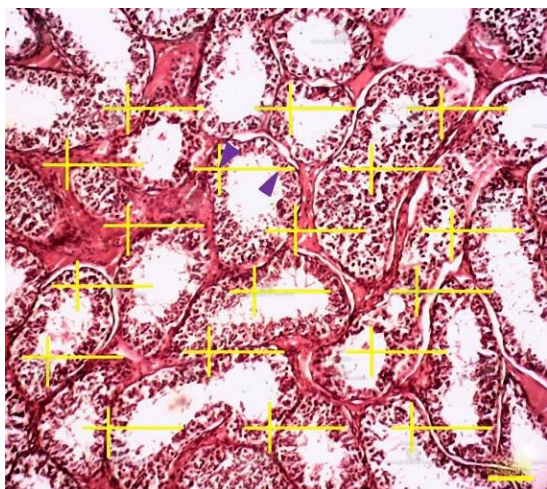


Figure 3. For estimating surface density, the total number of points (as upper arrowhead) superimpose on the germinal epithelium ($\sum p$), the length of each line (l/p), number of intersections (as lower arrowhead) of linear test probe with the inner surface of the germinal epithelium ($\sum l$) were calculated. The surface density (S_v) was then estimated using the following formula: $S_v = 2 \times \sum l / \sum p \times l / p$ (Hematoxyline and Eosin , $\times 100$, scale bar: 50 μm).

Estimation of Leydig cells number

Total number of Leydig cells per testis was estimated using physical dissector method [24]. Approximately 10 pairs serial sections were sampled from each testis. Two dissector probe (740 \times 740 μm) with exclusion lines (the left and lower borders) and inclusion lines (the right and upper borders) were superimposed on the images of the first section as the reference plane (figure 4a) and second section as the look-up plane (figure 4b) at the total magnification 400x. The counting rules of physical dissector were applied. A cell was considered if it was found in the reference plane but not in the look up plane as well as didn't hit the lower and left lines of the probe. At least 200 cells per testis were counted. The numerical density was estimated using:

$$N_v = \sum Q / a (\text{frame}) \times h \times \sum P$$

where $\sum Q$ is sum of the counted cells, a (frame) is probe area, $\sum P$ is total number of the examined fields and h is dissector height.

The Leydig cells were recognized in the interstitium as relatively large ovoid shaped cell with an eccentric nucleus. The nucleus contained a prominent nucleolus and peripherally localized

chromatin. The total number of the Leydig cells was estimated by multiplying the numerical density by the testis final volume.

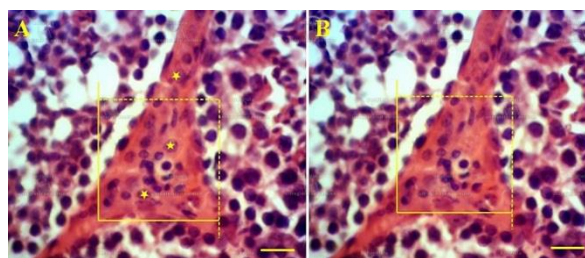


Figure 4. Physical dissector method for estimating the numerical density of Leydig cells. The images of a pair section (first and second sections) were used as the reference plane (A) and look-up plane (B), respectively. An unbiased counting frame was superimposed on the sample sections. Cellular profiles were counted if they contained completely or partly in the frame and did not touch the exclusion unbroken lines) as well as if they disappeared in the look-up plane (here 2 cells, Hematoxyline and Eosin $\times 400$, scale bar: 15 μm).

Statistical analysis

The data were expressed as Mean \pm standard deviation. One-way analysis of variance (ANOVA) followed by Tukey's *post-hoc test* at the significance level of $p \leq 0.05$ was used to compare the mean groups statistically.

Results and Discussion

The results of histological examination showed that testicular tissue in the control group had a normal appearance regarding seminiferous architecture and interstitial tissue arrangement (figure 5A). The testis of dianabol treated mice showed degenerative changes, disruption of spermatogenic cell line in germinal epithelium and interstitial tissue depletion (figure 5B). Treatment with different doses of curcumin could remarkably improve these changes and normalized the testicular tissue (figure 6A, 6B and 6C).

Body weight did not show any significant differences between control and experimental groups. Testis weight and volume decreased significantly ($p \leq 0.05$) in dianabol treated mice in comparison with the control group. Treatment of curcumin with every three used doses ameliorated the reduction of testis weight and volume (table 1). Although the testis volume in high dose (200 mg/kg) of curcumin was lower than medium dose (100 mg/kg), this difference was not significant ($p \leq 0.05$) (table 1).

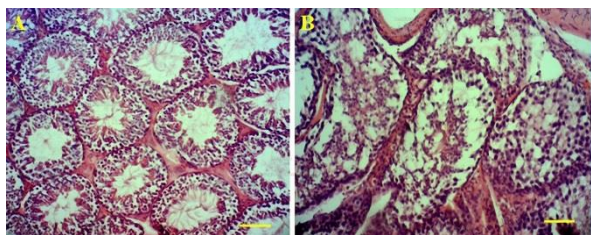


Figure 5. Histological sections of the testis in: control group with normal architecture (A) and in dianabol group treated with 20 mg/kg of dianabol (B). Degenerative changes, disruption of spermatogenic cell line in germinal epithelium and interstitial tissue depletion (Hematoxyline and Eosin $\times 100$, scale bar: 50 μm).

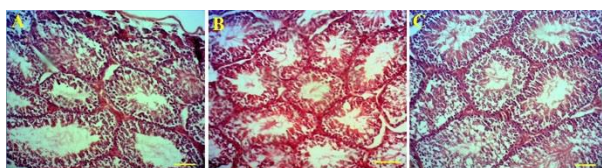


Figure 6. Histological sections of the testis in the experimental groups which received dianabol plus curcumin at doses 50 mg/kg (A), 100 mg/kg (B), and 200 mg/kg (C) (Hematoxyline and Eosin $\times 100$, scale bar: 50 μm).

Table 1. Body weight (g), testis weight (mg), and testis volume (mL) in the control, dianabol and curcumin treated mice. The results have been expressed as mean \pm SD.

Groups (n=)	Body weigh	Testis weight	Testis volume
Control	37.21 \pm 1.91 ^a	80 \pm 17.31 ^b	57.22 \pm 5.93 ^a
D	35.48 \pm 1.94 ^a	62.45 \pm 20.03 ^d	48.33 \pm 9.26 ^b
D+C50	32.61 \pm 2.3 ^a	78 \pm 16.43 ^b	54.00 \pm 15.55 ^a
D+C100	34.41 \pm 3.36 ^a	70.61 \pm 21.21 ^c	59.62 \pm 5.87 ^a
D+C200	33.00 \pm 2.12 ^a	86.66 \pm 13.66 ^a	55.58 \pm 8.82 ^a

D: 20 mg/kg dianabol treated group; D+C50: dianabol plus 50 mg/kg curcumin treated group; D+C100: dianabol plus 100 mg/kg curcumin treated group; D+C200: dianabol plus 200 mg/kg curcumin treated group; different superscripts in the same column indicate significant difference ($p \leq 0.05$) between groups.

The volume of seminiferous tubules decreased significantly ($p \leq 0.05$) in dianabol treated mice, while interstitial tissue volume increased as compared to the control. The changes were ameliorated in all the animals treated with curcumin (table 2). Tubule length and diameter decreased significantly ($p \leq 0.05$) in mice treated with dianabol compared to the control. Tubule length increased significantly ($p \leq 0.05$) with high dose of curcumin as compared to the dianabol treated mice. Tubule diameter demonstrated significant increase ($p \leq 0.05$) with all doses of curcumin compared to the dianabol treated mice (table 2). Height of germinal epithelium decreased significantly ($p \leq 0.05$) following dianabol administration and improved with high dose of curcumin in comparison with dianabol treated mice (table 2). The number of Leydig cells decreased significantly ($p \leq 0.05$) in dianabol

treated groups as compared to the control group. Treatment with high or intermediate doses of curcumin ameliorate this change and the number of cells increased significantly ($p \leq 0.05$) (table 2). Overall, by comparing the effect of high dose of curcumin with low and medium doses, it was obvious that all desired parameters improved toward normal level in a way that there was no significant difference between high dose of curcumin and control group (table 2).

In the present study, the negative effects of long-term use of dianabol (an anabolic androgenic steroid) on the testicular tissue structure as well as possible protective effects of curcumin against these adverse effects were investigated. The obtained results showed that eight weeks administration of dianabol at the dose of 20 mg/kg, resulted in significant changes in the volume of the testis and its internal structures (seminiferous tubules and interstitial tissue) as well as in the arrangement of the spermatogenic cell line. These alterations were ameliorated in animals which had received curcumin.

At the end of the experiment, there was no significant difference between body weight of dianabol treated mice and other groups. Among the previous reports, there are contradictions about the reduction or increase in body weight of animals receiving anabolic steroids, which is mainly related to the dosage and the duration of the treatment. Hijazi et al. have revealed that the body weight increased in rat treated with testosterone [25]. This could be due to water retention and reduction in low density lipoprotein (LDL) [26,27]. In contrast, it has been reported that nondrolone decaoanate at the dose of 3 mg/kg for 8 weeks did not affect the rats body weight [28]. In the present study, weight and volume of the testis showed significant decrease after oral administration of dianabol compared to the control group. Mutalip et al. have compared testosterone, stanozolol, and nondrolone and showed that the highest reduction in the testis volume was due to stanozolol and the least effect was due to nandrolone [29]. These discrepancies could be attributed to the molecular structure of the synthetic AAS and different doses used. In another study, administration of high dose of nondrolone (10 mg/kg) for 14 weeks caused significant decrease in the testis weight [30]. Also, Feinberg et al. reported that administration of testosterone propionate before or after puberty caused a significant reduction in the testis weight [31].

Table 2. Total volume (mm³) of the seminiferous tubules and interstitial tissue, tubules length (m) and diameter (μm), height of the germinal epithelium of the tubules (μm) and Leydig cells number ($\times 10^6$) in the control, dianabol and curcumin treated mice. The results have been expressed as mean \pm SD

Groups	Tubule volume	Interstitial tissue volume	Tubule length	Tubule diameter	Germinal epithelium height	Leydig cell number
Control	41.22 \pm 2.86 ^a	12.41 \pm 2.07 ^a	2.11 \pm 0.35 ^a	208 \pm 11.31 ^a	48.61 \pm 4.39 ^a	2.02 \pm 0.38 ^a
D	28 \pm 1.78 ^c	15 \pm 2.61 ^b	1.11 \pm 0.25 ^c	154.1 \pm 23.81 ^b	36.66 \pm 2.58 ^c	1.21 \pm 0.32 ^c
D+C50	36.41 \pm 3.36 ^b	12.81 \pm 1.92 ^a	1.61 \pm 0.26 ^b	188 \pm 20.16 ^a	42 \pm 3.67 ^b	1.51 \pm 0.29 ^b
D+C100	42.21 \pm 6.09 ^a	12.42 \pm 1.51 ^a	2.01 \pm 0.34 ^b	207 \pm 20.16 ^a	45 \pm 4.85 ^b	2.04 \pm 0.36 ^a
D+C200	40.83 \pm 6.79 ^a	11.16 \pm 2.13 ^a	1.82 \pm 0.29 ^a	205.6 \pm 16.31 ^a	49.2 \pm 6.97 ^a	2.01 \pm 0.51 ^a

D: 20 mg/kg dianabol treated group; D+C50: dianabol plus 50 mg/kg curcumin treated group; D+C100: dianabol plus 100 mg/kg curcumin treated group; D+C200: dianabol plus 200 mg/kg curcumin treated group; different superscripts in the same column indicate significant difference ($p \leq 0.05$)

Decrease in testis volume after dianabol administration precisely confirms the testicular atrophy. Since the seminiferous tubules constitute the bulk of the testicular tissue, reduction in tubules volume is expected following testicular atrophy. Accordingly, the present findings revealed significant decrease in tubules volume after treatment with dianabol. Decrease of the seminiferous tubules volume following the AAS administration can affect spermatogenesis process and lead to a decrease in the height of germinal epithelium as well as decrease in the length and diameter of the tubules [30]. So, the changes of length, diameter and height of germinal epithelium should be considered when the testicular atrophy occurs. Stereological procedures allow these parameters to be precisely estimated. These parameters (length, diameter and epithelium height) showed significant decrease in danabol treated mice compared to the control group. It has been shown that high doses of nandrolone decreased the length of tubules significantly and along with this decrease, sperm count has reduced [30]; while, it has been established that exogenous testosterone exerts negative feedback effects on the hypothalamic-pituitary axis and inhibits the secretion of LH and FSH hormones. However, following the administration of AAS, normal and increased levels of androgens have been observed, but these concentrations could not provide the intratesticular concentration necessary for spermatogenesis [32]. Therefore, upon the use of these compounds, hypogonadotropic hypogonadism and subsequently testicular atrophy will occur. Overall, the intratesticular concentration of testosterone is essential to maintain the normal length and diameter of the seminiferous tubules [32].

Dianabol with doses 10, 20 and 40 mg/kg for 8 weeks caused a reduction in alive sperm and

deformities of sperm head and tail in rat [33]. These results suggest that dianabol can exert such effects by possibly interfering with hypothalamic-pituitary-gonad axis and consequently disrupting spermatogenesis in the seminiferous tubules. Khder and Falah [34] stated that sperm reduction can be caused by increased production of free radicals and apoptosis of spermatogenic and somatic cells following AAS administration. Reduction in sperm count could also be attributed to the decrease of intratesticular testosterone level; so, there is a close relationship between serum level of intratesticular testosterone and spermatogenesis [35]. Given that Leydig cells number has decreased significantly in dianabol treated mice, this change could lead to reduction of the testosterone level and spermatogenesis. On the other hand, decrease in intratesticular testosterone initiates apoptosis pathways in spermatogenic cells. In addition, it has been well documented that testosterone administration induces oxidative stress [36]. So, inhibition of spermatogenesis cannot be solely due to the decrease in intratesticular testosterone level, but beside hormonal changes, this decrease leads to apoptosis induction and free radical production in testis which consequently disturbs spermatogenesis.

Different doses of curcumin were used in the present study to improve the adverse effects of dianabol on testicular tissue structure. Recently, curcumin has been used as a complementary medication for treating gastritis [37], asthma [38] and diabetes [39]. The results of in vivo and in vitro studies have revealed that curcumin has antioxidant, anti-cancer, anti-virus, anti-inflammatory and anti-rheumatism effects [40]. In addition, curcumin protective effects have been reported in various toxicities such as cisplatin and sodium arsenite toxicity [16,18],

afatoxin toxicity [17,36], and dexamethasone toxicity [41]. The obtained results showed that curcumin at 100 and 200 mg/kg doses could remarkably improve the structural changes including Leydig cell number and germinal epithelium height in the testis of the dianabol treated animals. Due to the decrease of Leydig cells number in the dianabol treated mice and amelioration of this changes with high doses of curcumin, it could be concluded that curcumin can inhibits Leydig cells apoptosis and thereby increases testosterone synthesis in testicular tissue. Giannessi et al. revealed that alcohol treatment could decrease testosterone level and in contrast, curcumin plus alcohol could improve testosterone level [42]. Therefore, the amelioration of examined parameters probably can be attributed to the direct antioxidant effects of curcumin and its inhibitory effects on the production of free radicals. Khorsandi et al. in their study about the protective effect of curcumin in dexamethasone induced testicular toxicity showed that curcumin administration increased the expression of the anti-apoptotic factor Bcl-2 and also increased the diameter of seminiferous tubules [41]. Improving the concentration of intratesticular proteins following administration of aqueous solution of curcumin could enhance sperm maturation and these effects reflected the androgenic potential of this plant [41].

It could be concluded that dianabol can induce remarkable changes in the structural parameters of the seminiferous tubules and Leydig cells and curcumin with high doses can ameliorate these effects.

Acknowledgments

This article was a part of the thesis by Omid Baharan to fulfill the requirements for earning the DVM degree. The authors gratefully acknowledge the financial support of Razi University.

Author contributions

Omid Baharan conducted the experimental procedure and animal handling. Nader Goodarzi designed the stereological method and prepared the manuscript.

Declaration of interest

The authors declare that there is no conflict of interest. The authors alone are responsible for the content of the paper.

References

- [1] Foss GL, Simpson SL. Oral methyltestosterone and jaundice. *Br Med J*. 1959; 1(5117): 259-263.
- [2] Foss GL. Some experiences with a new anabolic steroid (methandrostenolone). *Br Med J*. 1960; 1(5182): 1300-1305.
- [3] Moss JL, Crosnoe LE, Kim ED. Effect of rejuvenation hormones on spermatogenesis. *Fertil Steril*. 2013; 99(7): 1814-1820.
- [4] Shahidi NT. A review of the chemistry, biological action, and clinical applications of anabolic- androgenic steroids. *Clin Ther*. 2001; 23(9): 1355-1390.
- [5] Shahidi NT, Diamond LK. Testosterone-induced remission in aplastic anemia of both acquired and congenital types. Further observations in 24 cases. *N Engl J Med*. 1961; 264(19): 953-967.
- [6] Coward RM, Rajanahally S, Kovac JR, Smith RP, Pastuszak AW, Lipshultz LI. Anabolic steroid induced hypogonadism in young men. *J Urol*. 2013; 190(6): 2200-2205.
- [7] Hartgens F, Kuipers H. Effects of androgenic-anabolic steroids in athletes. *Sports Med*. 2004; 34(8): 513-554.
- [8] Fronczak CM, Kim ED, Barqawi AB. The insults of illicit drug use on male fertility. *J Androl*. 2012; 33(4): 515-528.
- [9] Garevik N, Strahm E, Garle M, Lundmark J, Stahle L, Ekstrom L, Ekstrom L, Rane A. Long term perturbation of endocrine parameters and cholesterol metabolism after discontinued abuse of anabolic androgenic steroids. *J Steroid Biochem Mol Biol*. 2011; 127(3-5): 295-300.
- [10] Boregowda K, Joels L, Stephens JW, Price DE. Persistent primary hypogonadism associated with anabolic steroid abuse. *Fertil Steril*. 2011; 96(1): 7-8.
- [11] Parkinson AB, Evans NA. Anabolic androgenic steroids: a survey of 500 users. *Med Sci Sports Exerc*. 2006; 38(4): 644-651.
- [12] Glusker J. Intermolecular interactions around functional groups in crystals: data for modeling the binding of drugs to biological macromolecules. *Acta Crystallogr*. 1995; 51(4): 418-427.
- [13] Agarwal A, Nallella K, Allamaneni S, Said T. Role of antioxidants in treatment of male infertility: an overview of the literature. *Reprod Biomed Online*. 2008; 8(6): 616-627.
- [14] Daniel S, Limson J, Dairam A, Watkins G,

- Daya S. Through metal binding curcumin protects against lead-and cadmium induced lipid peroxidation in rat brain homogenates and against lead-induced tissue damage in rat brain. *J Inorg Biochem.* 2004; 98(2): 266-275.
- [15] Jungil H, Mousumi B, Jihyeuny J, Jae-Ha R, Xiaoxin C, Shengmin S. Modulation of arachidonic acid metabolism by curcumin and related B-diketone derivatives: effect on cytosolic phospholipase A, cyclooxygenases and 5- lipoxygenase. *Carcinogenesis.* 2004; 25(9): 1671-1679.
- [16] Ilbey YO, Ozbek E, Cekmen M, Simsek A, Otunctemur A, Somay A. Protective effect of curcumin in cisplatin-induced oxidative injury in rat testis: mitogen-activated protein kinase and nuclear factor-kappa B signaling pathways. *Hum Reprod.* 2009; 24(7): 1717-1725.
- [17] Mathuiria N, Verma RJ. Curcumin ameliorates aflatoxin-induced lipid peroxidation in liver, kidney and testis of mice – an *in vitro* study. *Acta Pol Pharm.* 2007; 64(5): 413-416.
- [18] El-Demerdash FM, Yousef MI, Radwan FM. Ameliorating effect of curcumin on sodium arsenite-induced oxidative damage and lipid peroxidation in different rat organs. *Food Chem Toxicol.* 2009; 47(1): 249-254.
- [19] Karbalay-Doust S, Noorafshan A. Ameliorative effects of curcumin on the spermatozoon tail length, count, motility and testosterone serum level in metronidazole-treated mice. *Prague Med Report.* 2011; 112(4): 288-297.
- [20] Silva MAJ, Merzel J. Stereological determination of the volume of the rat hemimandible rat tissue. *Anat Rec.* 2001; 263(3): 255-259.
- [21] Gundersen HJ, Bendtsen TF, Korbo L, Marcussen N, Moller A, Nielsen K. Some new, simple and efficient stereological methods and their use in pathological research and diagnosis. *J Pathol Microbiol Immunol.* 1988; 96(5): 379-394.
- [22] Nyengaard JR. Stereologic methods and their application in kidney research. *J Am Soc Nephrol.* 1999; 10(5): 1100-1123.
- [23] Mandarim-de-Lacerda CA. Stereological tools in biomedical research. *An Acad Bras Cienc.* 2003; 75(4): 469-486.
- [24] Sterio DC. The unbiased estimation of number and sizes of arbitrary particles using the disector. *J Microsc.* 1984; 134(2): 127-136.
- [25] Mazhar Hijazi M, Ahmed Azmi M, Hussain A, Naqvi SNH, Perveen R, Hijazi S. Androgenic anabolic steroidal-based effects on the morphology of testicular structures of albino rats. *Pak J Zool.* 2012; 44(6): 1529-1537.
- [26] Pope HGJR, Katze DL. Psychiatric and medical effects of anabolic-androgenic steroids use. A controlled study of 160 athletes. *Arch Gen Psychiat.* 1994; 51(5): 375-382.
- [27] Smith DA, Perry PJ. The efficacy of ergogenic agents in athletic competition. Part I: Androgenic-anabolic steroids. *Ann Pharmacother.* 1992; 26(4): 520-528.
- [28] Karbalay-Doust S, Noorafshan A. Stereological study of the effects of nandrolone decanoate on the rat prostate. *Micron.* 2007; 37(7): 617-623.
- [29] Mutalip SSM, Singh SGK, Shah MA, Mohamad M, Mani V, Hussin SN. Histological changes in testes of rats treated with testosterone, nandrolone, and stanozolol. *Iran J Reprod Med.* 2013; 11(8): 653-658.
- [30] Noorafshan A, Karbalay-Doust S, Mesnah-Ardekani F. High doses of nandrolone decanoate reduces volume of testis and length of seminiferous tubules in rats. *Revis.* 2005; 113(2): 122-125.
- [31] Feinberg MJ, Lumia AR, McGinnis MY. The effect of anabolic-androgenic steroids on sexual behavior and reproductive tissues in male rats. *Physiol Behav.* 1997; 62(1): 23-30.
- [32] Dohle GR, Smit M, Weber RF. Androgens and male fertility. *World J Urol.* 2003; 21(5): 341-345.
- [33] Adnan MJ, Alzamey AN, Hamad AG. Study of the testicular damage induced by dianabol and its effect on morphological and histological changes in albino male rats. *J Agri Vet Sci.* 2015; 8(8): 24-32.
- [34] Khder HR, Falah MA. The effect of sustanon (testosterone derivatives) taken by athletes on the testis of rat. *Jordan J Biol Sci* 2012; 5(2): 113-119.
- [35] Zirkin BR, Santulli R, Awoniyi CA, Ewing LL. Maintenance of advanced spermatogenic cells in the adult rat testis: quantitative relationship to testosterone concentration within the testis. *Endocrinol.* 1989; 124(6): 3043-3049.

- [36] Alonso-Alvarez C, Bertrand S, Faivre B, Chastel O, Sorci G. Testosterone and oxidative stress: the oxidation handicap hypothesis. *Proc Biol Sci.* 2007; 274(1611): 819-825.
- [37] Mei X, Xu D, Xu S, Zheng Y, Xu S. Novel role of Zn(II)-curcumin in enhancing cell proliferation and adjusting proinflammatory cytokine-mediated oxidative damage of ethanol-induced acute gastric ulcers. *Chem Biol Interact.* 2012; 197(1): 31-39.
- [38] Ma C, Ma Z, Fu Q, Ma S. Curcumin attenuates allergic airway inflammation by regulation of CD4+CD25+ regulatory T cells (Tregs)/Th17 balance in ovalbumin-sensitized mice. *Fitoterapia.* 2013; 87: 57-64.
- [39] Kanitkar M, Gokhale K, Galande S, Bhonde RR. Novel role of curcumin in the prevention of cytokine-induced islet death in vitro and diabetogenesis in vivo. *Br J Pharmacol.* 2008; 155(5): 702-713.
- [40] Cole GM, Teter B, Frautschy SA. Neuroprotective effects of curcumin. *Adv Exp Med Biol.* 2007; 595: 197-212.
- [41] Khorsandi L, Mirhoseini M, Mohamadpour M, Orazizadeh M, Khaghani S. Effect of curcumin on dexamethasone-induced testicular toxicity in mice. *Pharm Biol.* 2013; 51(2): 206-212.
- [42] Giannessi F, Giambelluca MA, Grasso L, Scavuzzo MC, Ruffoli R. Curcumin protects Leydig cells of mice from damage induced by chronic alcohol administration. *Med Sci Monit.* 2008; 14(11): 237-242.

Abbreviations

LDL: low density lipoprotein; IUR: isotropic uniform random; TNF: tumor necrosis factor; IL: interleukin; PLA₂: phospholipase A₂; COX: cyclooxygenase; LOX: lipoxygenase; AAS: anabolic androgenic steroids