



Persian Traditional Medicine in Treatment of Ulcerative Colitis: a Case Report

Hamid Reza Rostamani^{1,2} , Shahryar Semnani³, Mahdi Yousefi^{1*} 

¹Department of Persian Medicine, School of Persian and Complementary Medicine, Mashhad University of Medical Sciences, Mashhad, Iran.

²Health Management and Social Development Research Center, Golestan University of Medical Sciences, Gorgan, Iran.

³Golestan Research Center of Gastroenterology and Hepatology, Golestan University of Medical Sciences, Gorgan, Iran.

Abstract

Background and objectives: Ulcerative colitis (UC) is a chronic inflammatory bowel disease. Herbal medicines such as *Persicaria bistorta*, *Pistacia lentiscus*, *Punica granatum*, and *Myrtus communis* manifesting a variety of pharmacological properties and effects, have been widely implicated in the treatment of UC. We report a case of UC in a 42-year-old male patient. **Methods:** The patient presented frequent passage of bloody stool, severe cramping, and abdominal pain. This was accompanied by fatigue, excessive mucus, and pus in the stool. He had a 12 years prehistoric diagnosis of ulcerative colitis and received conventional therapy, which yielded no improvement in the symptoms. His regimen was then switched to the Persian traditional treatment employing the “Sahj” formula (including *Persicaria bistorta*, *Pistacia lentiscus*, *Boswellia frereana*, *Punica granatum*, and *Myrtus communis*) for 4 months. **Results:** After 18 days of traditional therapy with “Sahj” tablet, there was a significant improvement in his UC symptoms as evidenced in the increased frequency of his bowel movements (twice daily), absence of bloating, cramping, or abdominal pain and a normal bloodless stool. A colonoscopy report and digital rectal examination 4 months post-treatment, revealed a normal perianal area, cecum, and terminal ileum.

Conclusion: The results suggest that the Persian traditional “Sahj” medicine possesses pharmacological properties that render it effective in the treatment of UC and mucosal diseases. However, further clinical trials are needed to evaluate and confirm the efficacy and safety of “Sahj” therapy.

Keywords: herbal medicine; Persian medicine; ulcerative colitis

Citation: Rostamani HR, Semnani Sh, Yousefi M. Persian traditional medicine in treatment of ulcerative colitis: a case report. Res J Pharmacogn. 2021; 8(1): 1-6.

Introduction

Ulcerative colitis (UC) is a chronic inflammatory bowel disease of the colon and rectum which causes long-term inflammation and ulceration of the mucosa [1,2]. Ulcerative colitis is a worldwide disease with an increasing prevalence that varies between 0.5 and 238 per 100,000 people per year, depending on the development state of the countries (developed or developing

[3]. Inflammatory bowel disease (IBD) is considered as an important public health issue due to its recurrent and progressive clinical course, as well as its impact on the quality and social life of young people, including their ability to work and acquire new skills [3].

The gold standard treatment for UC has been surgery and administration of medications such

*Corresponding author: YousefiM@mums.ac.ir

as 5-aminosalicylic acid, corticosteroid, biologic therapies, and immune-suppressants [4]. However, some patients receiving these conventional drug regimens fail to achieve clinical improvement, which poses a serious barrier to the successful management of UC according to published reports [1,2]. As a result, alternative novel therapeutic options such as traditional and herbal medicines have been actively investigated, and some have already been introduced into the clinic [5,6].

Currently, there has been an effective and ongoing development of traditional therapy for the treatment of UC in preclinical and clinical studies. Many herbal remedies have been widely implicated in traditional medical systems, and these orchestrate a variety of remedial pharmacologic effects on UC via analgesic, anti-bacterial, anti-inflammatory and anti-diarrheal effects as well as regulation of immune response, inhibition of macrophage/monocyte, growth inhibition of T- and B-lymphocytes, and granulocyte activities [7,8]. Major natural constituents including tannins, flavonoid glycosides and aglycones, phenolics, and phenolic glycosides have exhibited efficacy in preclinical studies, improving symptoms, and reducing the medical costs for UC patients [8]. Thus far, it has been reported that phenolic and polyphenols are the active chemical ingredients of *Persicaria bistorta* (L.) Samp., *Pistacia lentiscus* L., *Boswellia frereana* Birdw., *Punica granatum* L., and *Myrtus communis* L.

On the other hand, in Persian traditional medicine terminology, “Sahj” refers to a scratch or wound in the inner surface of the intestine, accompanied by abdominal pain and bleeding that can trigger bloody diarrhea [9,10]. According to published reports, UC and Crohn's disease which are the two main types of IBD have the closest relation to the intestinal “Sahj” [11,12]. Hence, this study aimed at evaluating the UC protective effect of these herbs clinically, based on the Persian traditional medicine use of these plants for the “Sahj” treatment [13], and also to record the pharmacological evidences in patients with ulcerative colitis.

Material and Methods

Ethical considerations

The study was a case report of a registered clinical trial with IRCT number:

IRCT201705201264N10. The patient provided signed informed consent, and was free to withdraw from the study at any time.

Tablet preparation

The “Sahj” tablet is composed of: roots of *Persicaria bistorta* (L.) Samp. (20 g), *Pistacia lentiscus* L. gum (30 g), *Boswellia frereana* Birdw. Gum (30 g), Armenian clay (20 g), the flower of *Punica granatum* L. (20 g), and the leaves of *Myrtus communis* L. (20 g). Preparation of the tablet performed done at the laboratory of the School of Persian and Complementary Medicine, Mashhad University of Medical Sciences. During the process, the samples were ground separately, sifted, and then mixed with a little bit of sumac distilled water. Then, these were transformed into tablets as previously described in the Persian Traditional Medicine resources [13].

Case presentation

A 42-year-old male (BW: 94 kg; height: 175 cm, employee with a bachelor's degree) attended a traditional medicine clinic on the 11th of September 2018, with an active UC that had existed for 12 years (recurrent case), having the following complaints: frequent passage of stool (15-20 times) with blood, severe cramping and abdominal pain (score 7), fatigue (severe with lethargy), and excessive mucus and pus in the stool. During defecation, there was a burning sensation and severe pain, along with urgency and tenesmus; the pain disseminated to the abdomen, with naturally occurring cramps in the stomach, either empty or when full, after eating; hemorrhoids with itching and burning

Differential diagnosis

Colonoscopy and biopsy of the patient indicated an acute colitis pattern with infectious (self-limited) colitis and Crohn's disease (Feb. 26, 2016) (Figure 1). The patient received sulfasalazine, prednisolone, and azathioprine. However, there was no remarkable improvement after about 20 days. Six months post-treatment, colonoscopy and biopsy were performed again. These confirmed the diagnosis of severe ulcerative colitis. Colonoscopy report: chronic crypt destructive colitis/acute phase/compatible with active UC (Aug. 3, 2016). He had been suffering continuously even after the prescription

of a few tablets, and there was still no remarkable improvement. Then, he decided to start an Persian traditional medical treatment (Sep.11,2018).

Treatment

The patient received the tablets (2 tablets/8 h/3 times daily) for 16 weeks. After one-week, the patient was additionally treated with Iron Plus (purchased from Shari company), given for preventing anemia; also, mint and fennel distilled water (half a glass of each per 6 hours) were administered to treat the feeling of fullness, increasing appetite, and bloating.

The following week, he started experiencing a feeling of fullness and flatulence. Then, he was additionally given Iron Plus (purchased from Shari company), mint, and fennel distilled water (half a glass of each per 6 hours). Also, colonoscopy was performed after 4 months to evaluate the effect of the treatment.

Results and Discussion

After one-week administration of the “Sahj” tablets (2 tablets/8 h/3 times daily), 80% of the cramping, abdominal pain (Score 5), and bleeding was reduced, and also the frequency of bowel movements was reduced to 3-4 times a day. The case presented an acute progressive active UC with symptoms. On the 18th day, after the administration of the “Sahj” tablets, his UC symptoms exhibited the following improvements: The frequency of bowel movements reduced to 2 times a day with mild excretion, and mild-to-moderate jaundice; no bloating; good appetite; no stress or cramps and abdominal pain; only felt slightly during defecation; no obvious bleeding, except in the form of mild veins with stool; stool with a normal consistency than the initial presentation; excretion of a viscous fluid (presumably mucus) along with the stool. Follow-up in the third week indicated a significant improvement in all his presented symptoms.

Overall, the patient satisfaction with the complementary therapeutic process of Persian traditional medicine was acceptable and he found the treatment process very useful.

After 4 months of ‘Sahj’ tablet administration (11th January, 2019), the colonoscopy report and the digital rectal examination (DRE), showed that the perianal area and the rectum were normal. Diffuse erosions were observed at the sigmoid and descending colon, while the rest of the colon

up to the cecum and terminal ileum appeared normal (Figure 2).

In Persian traditional medicine, *Persicaria bistorta* and *Punica granatum* have been used as astringents in the treatment of “Sahj” digestive disorders, particularly diarrhea and internal bleeding [13]. On the other hand, *Myrtus communis* leaves have been demonstrated to be hemostatic in any organ (anti-hemorrhagic), and have also been implicated in the treatment of diarrhea, hemorrhoids, prostatitis, bronchitis, sinusitis, tuberculosis, and cold. Also, in Iranian traditional medicine, *Pistacia lentiscus* and *Boswellia* have been used for more than 2,500 years, for the treatment of stomach and intestinal disorders such as gastric ulcers, dyspepsia, and peptic ulcer [13].

Some pre-clinical and clinical studies have documented the antioxidant, wound healing, and anti-inflammatory properties of herbs used in Persian traditional medicine for “Sahj” treatment. These properties are capable of changing the underlying molecular mechanisms of the oxidative and inflammatory conditions active in UC patients based on the ingredients present in the plants. Flavonoids and polyphenols which are the major compounds in this “Sahj” tablet can modify UC by ameliorating the derangement of intestinal microbiota, normalizing mucosal permeability, and ROS scavenging. These lead to the suppression of mucosal inflammation. Generally, polyphenols protect UC through the following actions. They increase endogenous antioxidant enzymes (SOD, CAT and GPx), diminish plasma levels of NO, PGE₂, LTB₄, and colonic mucosal MPO. They also modulate TNF- α , NF- κ B, I κ B α , IL-1 β , IL-6, IL-17, IL-22, COX-2, IFN- γ , and down-regulate the p38 MAPK and JNK pathways [14-23].

Traditionally, the Armenian clay was used as an isolated treatment in various diseases such as infected wounds, diarrhea, hemorrhage, etc. The medical effects of the Armenian clay have been associated with its astringent properties and mineral compounds including iron oxide, magnesium, and hydrous silicates [24]. Thus, the Persian traditional “Sahj” treatment using herbs rich in polyphenolic and terpenoid compounds can be implicated in the treatment of mucosal diseases and UC, with multiple mechanisms of action.

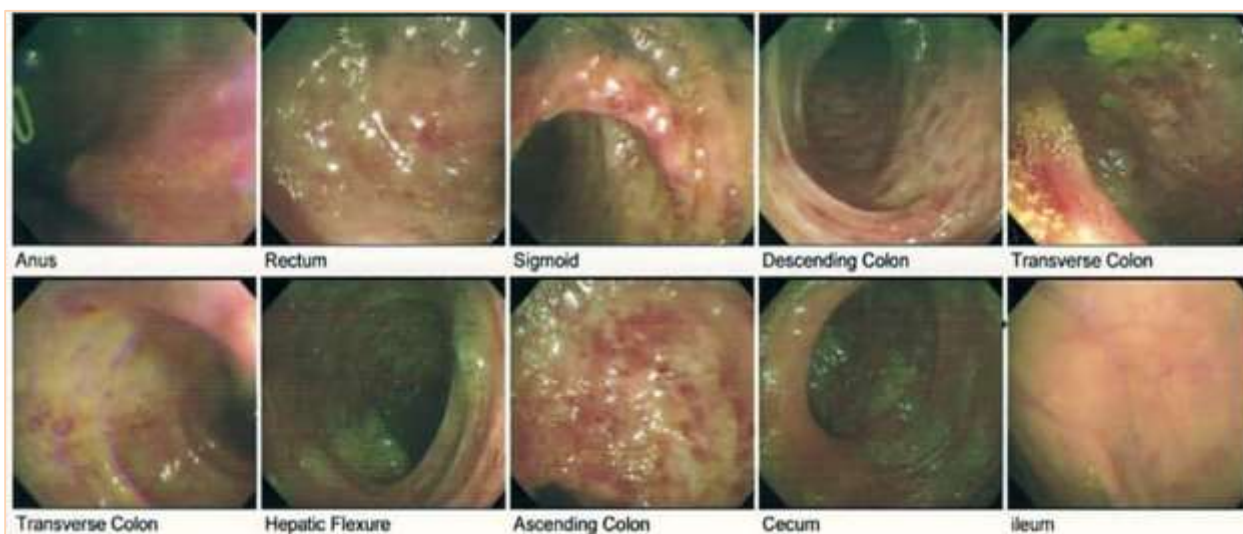


Figure 1. Gastrointestinal endoscopy; before the treatment: up to the terminal ileum was observed; erosions or erythematous area were seen throughout the rectum, colon up to the cecum, and terminal ileum.

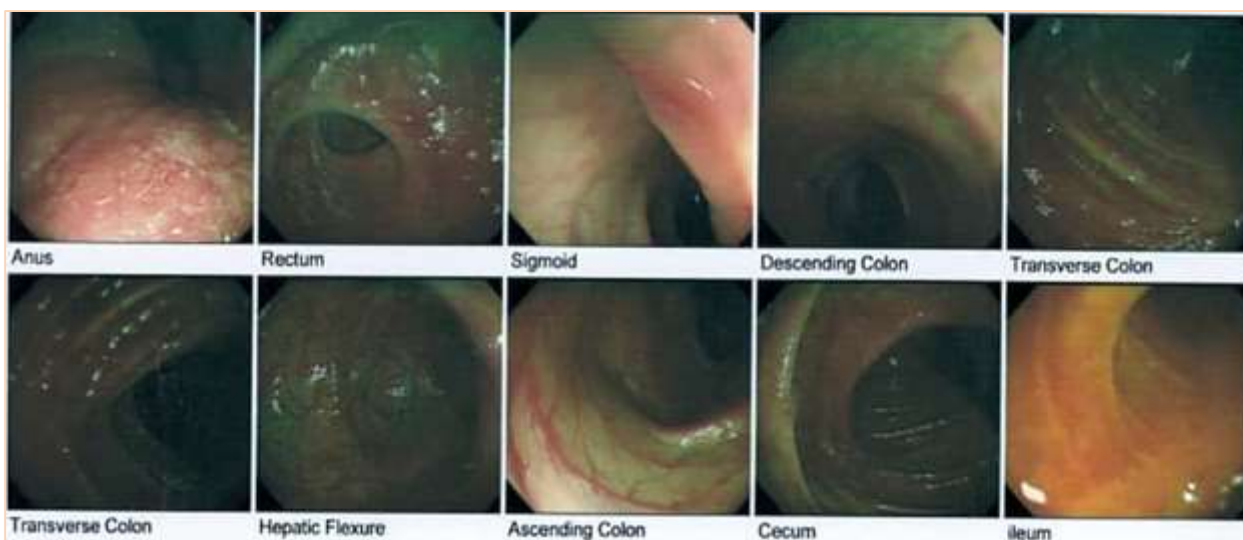


Figure 2. Colonoscopy of mucosal healing by “Sahj” tablet; a representative picture showing the perianal area and DRE (digital rectal exam) were normal; Diffuse erosions were observed at sigmoid and descending colon; the rest of the colon up to the cecum and terminal ileum appeared normal after 4 months treatment with “Sahj” tablet.

To date, ulcerative colitis is designated as a relapsing-remitting disease owing to its ability to perpetrate recurrent intestinal inflammation. Besides, conventional medications have not been successful in the treatment of patients with long-term ulcerative colitis, and they also exhibit severe adverse reactions [1].

Conclusion

The Persian traditional “Sahj” therapy can serve as an appropriate complement in the effective treatment of UC alongside conventional therapy. However, further clinical trials with larger sample size in an enhanced setting, are needed to

confirm the efficacy and safety of the “Sahj” therapy.

Acknowledgments

This article was derived from a PhD thesis and financially supported by Mashhad University of Medical Sciences, Mashhad, Iran (IR.MUMS.REC.1395.329) and Golestan University of Medical Sciences, Gorgan, Iran.

Author contributions

Mahdi Yousefi performed the supervision, conceived and designed the study, project

administration, manuscript review and submission; Hamid Reza Rostamani was involved in drug preparation, data analysis, patients' recruitment and follow up and preparing draft of the manuscript; Shahryar Semnani was involved in consultant and patients' recruitment and follow up.

Declaration of interest

The authors declare that there is no conflict of interest. The authors alone are responsible for the accuracy and integrity of the paper content.

References

- [1] Antonelli E, Villanacci V, Bassotti G. Novel oral-targeted therapies for mucosal healing in ulcerative colitis. *World J Gastroenterol*. 2018; 24(47): 5322-5330.
- [2] Naganuma M. Treatment with *Indigo naturalis* for inflammatory bowel disease and other immune diseases. *Immunol Med*. 2019; 42(1): 16-21.
- [3] César B, Lyra AC, Rocha R, Santana GO. Epidemiology, demographic characteristics and prognostic predictors of ulcerative colitis. *World J Gastroenterol*. 2014; 20(28): 9458-9467.
- [4] Naganuma M, Mizuno S, Nanki K, Sugimoto S. Recent trends and future directions for the medical treatment of ulcerative colitis. *Clin J Gastroenterol*. 2016; 9(6): 329-336.
- [5] D'Inca R, Garribba AT, Vettorato MG, Martin A, Martines D, Di Leo V, Buda A, Sturniolo GC. Use of alternative and complementary therapies by inflammatory bowel disease patients in an Italian tertiary referral center. *Dig Liver Dis*. 2007; 39(6): 524-529.
- [6] Ke F, Yadav PK, Ju LZ. Herbal medicine in the treatment of ulcerative colitis. *Saudi J Gastroenterol*. 2012; 18(1): 3-10.
- [7] Sałaga M, Zatorski H, Sobczak M, Chen C, Fichna J. Chinese herbal medicines in the treatment of IBD and colorectal cancer: a review. *Curr Treat Options Oncol*. 2014; 15(3): 405-420.
- [8] Lal UR, Singh IP. Review and implications of traditional Indian medicine for inflammatory bowel disease. [Accessed 2020]. Available from <https://www.intechopen.com/books/translational-studies-on-inflammation/review-and-implications-of-traditional-indian-medicine-for-inflammatory-bowel-disease>.
- [9] Sharifi Darani N, Cooper GM, Alizadeh Vaghasloo M. Introduction to the concept of crisis in diseases. *Trad Integr Med*. 2019; 4(4): 165-169.
- [10] Mosleh G, Nimrouzi M, Badr P, Abolhasanzadeh Z, Azadi A, Mohagheghzadeh A. The approach of traditional Persian medicine to treatment of anal fissure. *Trad Integr Med*. 2019; 4(2): 78-83.
- [11] Lamb CA, Kennedy NA, Raine T, Hendy PA, Smith PJ, Limdi JK, Hayee BH, Lomer MC, Parkes GC, Selinger C, Barrett KJ. British society of gastroenterology consensus guidelines on the management of inflammatory bowel disease in adults. *Gut*. 2019; 68(S3): 1-106.
- [12] Moradi Z, Besharat M, Ghorbanifar Z, Parsa-Yekta Z, Masroorchehr MR. Intestinal ulcer: review of diagnosis and treatment in persian medicine. *Sch J App Med Sci*. 2015; 3(1): 460-466.
- [13] Aghili Alavi Khorasani Shirazi MH. Makhzan-al-advieh. Kanpur: Bhagwan Dial, 1913.
- [14] Papada E, Forbes A, Amerikanou C, Torović L, Kalogeropoulos N, Tzavara C, Triantafyllidis JK, Kaliora AC. Antioxidative efficacy of a *Pistacia lentiscus* supplement and its effect on the plasma amino acid profile in inflammatory bowel disease: a randomised, double-blind, placebo-controlled trial. *Nutrients*. 2018; 10(11): 1-17.
- [15] Article R, Ansari SH, Siddiqui AN. *Pistacia lentiscus*: a review on phytochemistry and pharmacological properties. *Int J Pharm Pharm Sci*. 2012; 4(4): 16-20.
- [16] Asakura H, Kitahora T. Antioxidants and polyphenols in inflammatory bowel disease: ulcerative colitis and Crohn disease. 2nd ed. Academic Press, 2018.
- [17] Watson R, Preedy V, Zibadi SH. Polyphenols in human health and disease. Academic Press, 2013.
- [18] Lu Y, Zamora-Ros R, Chan S, Cross AJ, Ward H, Jakszyn P, Luben R, Opstelten JL, Oldenburg B, Hallmans G, Karling P, Grip O, Key T, Bergmann MM, Boeing H, Overvad K, Palli D, Masala G, Khaw KT, Racine A, Carbonnel F, Boutron-Ruault MC, Andersen V, Olsen A, Tjønneland A, Kaaks R, Tumino

- R, Trichopoulou A, Scalbert A, Riboli E, Hart AR. Dietary polyphenols in the aetiology of Crohn's disease and ulcerative colitis-a multicenter European prospective cohort study (EPIC). *Inflamm Bowel Dis*. 2017; 23(12): 2072-2082.
- [19] Triantafyllidi A, Xanthos T, Papalois A, Triantafyllidis JK. Herbal and plant therapy in patients with inflammatory bowel disease. *Ann Gastroenterol*. 2015; 28(2): 210-220.
- [20] Iram F, Khan SA, Husain A. Phytochemistry and potential therapeutic actions of boswellic acids: a mini-review. *Asian Pac J Trop Biomed*. 2017; 7(6): 513-523.
- [21] Papada E, Gioxari A, Amerikanou C, Forbes A, Tzavara C, Smyrnioudis I, Kaliora AC. Regulation of faecal biomarkers in inflammatory bowel disease patients treated with oral mastiha (*Pistacia lentiscus*) supplement: a double-blind and placebo-controlled randomised trial. *Phytother Res*. 2019; 33(2): 360-369.
- [22] Heydarpour F, Abasabadi M, Shahpiri Z, Vaziri S, Nazari H, Najafi F, Mirzaei M, Farzaei M. Medicinal plant and their bioactive phytochemicals in the treatment of recurrent aphthous ulcers: a review of clinical trials. *Pharmacogn Rev*. 2018; 12(23): 27-39.
- [23] Sisay M, Gashaw T. Ethnobotanical, ethnopharmacological, and phytochemical studies of *Myrtus communis* Linn: a popular herb in Unani system of medicine. *J Evid Based Complement Altern Med*. 2017; 22(4): 1035-1043.
- [24] Hosseinkhani A, Montaseri H, Mohagheghzadeh A, Seradj H, Sodaifi M. Armenian bole: a historical medicinal clay. *Pharm Hist*. 2014; 44 (4): 98-100.

Abbreviations

BW: body weight, CAT: catalase, COX-2: cyclooxygenase-2, DRE: digital rectal exam, GPx: glutathione peroxidase, IBD: inflammatory bowel disease, IFN- γ : interferon gamma, I κ B α : inhibitor of nuclear factor kappa B, IL-1 β : interleukin1 beta, IL-6: interleukin 6, IL-17: interleukin 17, IL-22: interleukin-22, LTB4: leukotriene B4, MPO: myeloperoxidase, NF- κ B: nuclear factor- κ B, NO: nitric oxide, PGE2: prostaglandin E₂, ROS: reactive oxygen species, RUT: rapid urease test, SOD: superoxide dismutase, ST: stomach, TNF α : tumor necrosis factor alpha, UC: ulcerative colitis.