





Royal Jelly Alleviates Side Effects of Doxorubicin on Male Reproductive System: A Mouse Model Simulated Human Chemotherapy Cycles

Mansour Safaei Pourzamani¹ , Shahrbanoo Oryan², Parichehr Yaghmaei¹, Cyrus Jalili³, Ali Ghanbari^{3*} 

¹Department of Biology, Science and Research Branch, Islamic Azad University, Tehran, Iran.

²Department of Biology, Faculty of Biological Sciences, Kharazmi University, Tehran, Iran.

³Medical Biology Research Center, Health Technology Institute, Kermanshah University of Medical Sciences, Kermanshah, Iran.

Abstract

Background and objectives: Doxorubicin, an effective anticancer agent, might impair the function of testicular tissue and lead to infertility. Royal jelly can heal male infertility because of its antioxidant activities. This study aimed to evaluate the histologic, genetic and biochemical repair potential of royal jelly on doxorubicin-induced male reproductive system side effects during eight chemotherapy cycles in mice. **Methods:** In this study, 77 male Balb/c mice (11 mice in each group) were divided to: no medication as sham group, normal saline (0.09%), royal jelly (50, 100 mg/kg), doxorubicin (2 mg/kg), and royal jelly+doxorubicin groups, receiving treatment once a week for six weeks. Histological and biochemical factors of male reproductive system were evaluated. **Results:** There was a significant reduction in testicular weight, spermatozoa parameters, diameter of seminiferous tubules, and total antioxidant capacity levels in the doxorubicin group compared to the control group ($p < 0.05$), whereas these parameters in the royal jelly (50, 100 mg/kg)+doxorubicin groups were significantly increased compared to the doxorubicin group ($p < 0.05$). Malondialdehyde, apoptotic index, and its regulatory genes were significantly higher in the doxorubicin group, while these parameters were decreased in the royal jelly (50, 100 mg/kg)+doxorubicin groups in comparison with the doxorubicin group ($p < 0.05$). **Conclusion:** Royal jelly protects male reproductive system damage induced by doxorubicin administration in mice. This protection was observed in both histological and biochemical respects. This beneficial effect of royal jelly can be attributed to its antioxidant properties.

Keywords: antineoplastic agents; antioxidant; apoptosis; royal jelly; toxicity

Citation: Safaei Pourzamani M, Oryan Sh, Yaghmaei P, Jalili C, Ghanbari A. Royal jelly alleviates side effects of Doxorubicin on male reproductive system: a mouse model simulated human chemotherapy cycles. *Res J Pharmacogn.* 2022; 9(1): 77–87 .

Introduction

Although doxorubicin as an antibiotic and anticancer drug has a high antitumor effect, its use in chemotherapy is limited due to the side effects in various non-target tissues, including the testes [1,2]. Doxorubicin impairs sperm motility, and strikingly impedes the process of spermatogenesis, leading to induction of testicular failure and eventually infertility [3-5].

Doxorubicin is commonly used to treat diverse types of tumors by targeting DNA and DNA-related enzymes. It inhibits DNA replication by interfering with the function of topoisomerase II and preventing DNA helix regeneration [6]. Doxorubicin can also induce histone eviction from chromatin, using this mechanism to prevent DNA replication. In addition, some studies have

* Corresponding author: aghanbari@kuma.ac.ir

shown that reactive oxygen species (ROS) production is another important factor in doxorubicin-induced tissue damage [7]. It has been demonstrated that oxygen radical-induced damage of lipids in the membrane is the key factor for doxorubicin-induced toxicity in testis and antioxidants can reduce this mechanism of inducing side effects [8].

Today, natural compounds with their unique properties such as low side effects, and availability have attracted the attention of researchers and therapists to relieve the side effects of the drugs such as doxorubicin [1,9-11]. Royal jelly is a commercial medical product. Its ingredients contain a variety of nutrients including proteins, sugars, fatty acids, vitamins (C and B), and minerals (iron, calcium, copper, potassium, magnesium, zinc, and sulfur) [12]. Royal jelly has several physiological and pharmacological effects including anti-inflammatory, anti-tumor, antioxidant, antihypertensive, hypoglycemic, and fertilization improvement activities [12-14].

In the case of oxidative stress, due to its antioxidant properties, royal jelly scavenges free radicals and neutralizes lipid peroxidation. This characteristic causes royal jelly to relieve oxidative stress-induced toxicity in the tissues such as the liver, kidney, and reproductive system [12]. A previous study demonstrated the protective effects of royal jelly on sperm toxicity and its beneficial effects on fertilization [14]. Although the efficacy of royal jelly for improving male reproductive parameters as well as the hazardous effect of doxorubicin on this system is known, the interaction of these two agents has not been studied. Thus, the present study aimed to examine the impact of royal jelly on doxorubicin -induced testicular toxicity in Balb/c mice. For this purpose, related histopathology, apoptosis, genetic and biochemistry evaluations were conducted. Moreover, special attention was considered for measuring the oxidative stress process, which is influenced by both royal jelly and doxorubicin.

Materials and Methods

Ethical considerations

The research protocol was approved by the Ethics Committee of Kermanshah University of Medical Sciences (IR.KUMS.REC.1397.475). All the animal experiments were carried out in accordance with the Helsinki guidelines and the

Ethics Committee of Kermanshah University of Medical Sciences.

This experimental study was designed on male mice and the sampling was the simple randomized method. The study was conducted in 2020 and purchasing all the materials was done by the researchers.

Chemicals

Royal jelly was purchased from Sigma (R0376. Sigma-Aldrich, US), the administrated doses were selected based on previous reports demonstrating the in vivo anti-inflammatory and antioxidant effects [15]. Doxorubicin was provided from Pharmacia and Upjohn, Italy. Xylazine was prepared from Alfasan co, Netherlands. The testicular tissue MDA levels was determined by MDA kit (Cat No: MDA-96A) from ZellBio GmbH, Germany. Total antioxidant status was estimated by a redox oxidation colorimetric assay kit (Cat No: TAC-96A) from ZellBio GmbH-Germany. The ELISA-kit (Cat.No.11544675001; Roche) based on manufacturer's instruction was used for analyze the apoptosis rate in homogenated testicular tissue sample. RNAeasy Plus Mini Kit (Qiagen, Germany) was used to extract total RNA.

Animals

The animals (77 inbred male Balb/c mice) were provided from Pasteur Institute, Tehran, Iran. They were transferred to the animal home (Science and Research Branch of Tehran Azad University, Tehran, Iran). The mice that were adults (two-months-old) and had a history of having children once with 28 ± 2 g weight were included, while immature mice; below two-months-old, not having children history with the weight below 26 g were excluded. Specific living conditions were provided including a 12-hour light/dark cycle, the controlled temperature of $22 \pm 2^\circ$ C, free access to standard diet pellets and water. The animals were kept for a week for adaption to the new environment.

Experimental design and animal grouping

We randomly divided 77 male Balb/c mice into 7 groups (11 mice per group) as follows: 1- Sham group: without any medication; 2- Control group: receiving normal saline (200 μ L) intraperitoneally; 3, 4- RJ1, 2 groups: treated with royal jelly at the doses of 50, and 100 mg/kg orally, respectively [15]; 5- DOX group:

receiving doxorubicin at a dose of 2 mg/kg soluble in 200 μ L normal saline intraperitoneally [16]; 6,7- DOX + RJ1, 2 groups: exposed to both doxorubicin (2 mg/kg) and the two doses 50, and 100 mg/kg of royal jelly, respectively.

Doxorubicin or normal saline treatments were done at 10 A.M. once a week, while royal jelly was administrated with daily gavage at 10 am. According to previous studies, 6 weeks and 24 hours after the last treatment; the mice were sacrificed in deep anesthesia by IP injection of ketamine and xylazine [17]. Then testis and epididymis tissues were extracted after testis weighing. The sperms were obtained from the epididymis.

Sperm analysis

To investigate the different parameters of spermatozoa, the epididymal tissue (tail area) that contained sperm was separated and shredded in a petri dish containing 5 mL DMEM/F12 medium containing 10% FBS with a razor blade. Petri dishes were then incubated in a CO₂ incubator (5%) at 37 °C for 20 min. To count the sperms, an equal volume ratio was obtained from the medium containing the sperm and formalin (10%), and by placing the resulting mixture on Neobar slides, the sperm were counted with a 100 magnification of a light microscope. In brief, 5 squares out of 25 central squares were selected similarly for all groups, and the sperm's heads completely inside the squares and those with more than half of their heads with internal perimeter lines were counted. Then, the mean sperm count was multiplied to 2 for considering formalin dilution and 0.05×10^6 for considering dilution [18]. Using light microscopy (400 \times), sperm motility was examined in 10 randomly zigzag selected fields for each sample. To evaluate the viability and morphology of spermatozoa, eosin Y staining was used. For this purpose, 10 microliters of media containing sperms were mixed with eosin Y dye (1%). Smearing a drop of the blend on a clean slide, morphology, and viability of 100 sperms via randomly selected fields were examined for each sample using a zigzag form of monitoring 400 magnification of a light microscope [19].

Histological examination of the testis

The left testis of the mice was chosen for histological evaluations by the conventional histological method (paraffin method). In this regard, they were initially fixed in 10% formal

saline for 3 days. It helps tissue fixation and prevention of tissue autolysis. Subsequent steps included: washing thoroughly under running water, dehydrating by rising doses of ethanol (50, 60, 70, 80, 90, and 100%, which included 3 minutes for each step; 100% ethanol step was repeated three times), clearing by xylene (three times and 10 min in each) and embedding in soft paraffin (3 times and 15 minutes in each). The paraffin blocks were prepared and 5- μ m histological sections were cut by a rotary microtome (Leica RM2125, Mumbai, India). Afterward, the sections were consequently embedded in descending rate of ethyl alcohol toward distilled water, and finally in hematoxylin and eosin dyes. The stained slides were photographed by a light microscope attached to a DP12 camera with a resolution of 3.34 million pixels. For each sample, by a zigzag form, we monitored at least 5 and 50 captured tissue specimens with magnifications of 100 and 400, respectively to include at least 100 round tubules. Photos with 100 magnifications were used to calculate Johnson's score for exploring spermatogenesis and schaemic changes in the testes and the degree of damage were evaluated with Cosentino scoring by means of calculating the average number of tubules and 400 magnifications for determining the diameter of the tubules. The Motic camera and software (AE-3; Motic S.L.C.) were used to calculate the outer diameter of the duct in micrometer [18,19]. Ischaemic changes in the testes and the degree of damage were evaluated with Cosentino scoring and the Johnson tubular biopsy score (JTBS). In Cosentino scoring, the testis is classified in 4 grades. Grades 1 to 4 stand for normal testis parenchyma to coagulation necrosis in the parenchyma. JTBS was developed to examine spermatogenesis histopatologically after testicular damaging circumstances. A Johnson score of 9 or 10 represents normal histology, a score of 8 hypospermatogenesis, 3-7 maturation arrest, 2 germinal cell aplasia and a score of 1, tubular fibrosis.

Malondialdehyde (MDA) measurement in testicular tissue

MDA level was measured as an indicator of lipid peroxidation. In this respect, a commercial MDA kit was used. Briefly, 0.2-0.3 g of the right testis tissues was homogenized by mixing the tissue with an ice-cooled 1.15% solution of potassium chloride and the samples were centrifuged for 10

minutes at 3000 g. Then, 0.5 mL of the supernatant was mixed with 3 mL phosphoric acid (1% V/V) and following vortex mixing, 2 mL of 6.7g/L Tertiary-Butyl Alcohol (TBA) was added to the samples. Next, the specimens were boiled for one hour at 95 °C and following the addition of 3 mL n-butanol, the samples were centrifuged (3000 g) for 10 minutes. The absorbance of the supernatant was measured by spectroscopy (Pharmacia, Novaspec II, Biochrom, England) at 550 nm. The amount of MDA was expressed as mmol/mL in comparison to the simultaneously prepared calibration curve using MDA standards.

Total antioxidant capacity (TAC) evaluation of testicular tissue

For TAC investigation, 0.2-0.3g of the right testis tissues was homogenized immediately to give 50% (w/v) homogenate in ice-cold medium containing 50 mM Tris-HCl and 300 mM sucrose. The homogenate was centrifuged at 500 g for 10 minutes at 4 °C. The supernatant (10%) was used for determination of TAC using commercial kits. The amount of TAC was measured by comparing the number of antioxidants present in the sample (one g of homogenized tissue) with ascorbic acid as the standard. Kit sensitivity was 0.1 mM. The results were analyzed by a Microplate Reader (Model 550, BioRad, Segrate, Milan, Italy) at 490 nm absorbance.

Cell death detection

The apoptosis rate in the homogenated testicular tissue sample was measured by ELISA-kit based on the manufacturer's instruction. In this technique, anti-histone antibodies were fixed on the walls of microplates. Blocking solution was hired for saturation of non-specific binding sites on the walls. Then, nucleosome binding was done via their histone components to the immobilized anti-histone antibody. Anti-DNA-peroxidase (POD) reacted with DNA-part of nucleosome. During washing, unbound peroxidase conjugate were removed from the sample. Finally, the 2,2'-azino-di-[3-ethylbenzthiazoline sulfonate?] (ABTS) was used for analysis of peroxidase levels and measured by an ELISA reader under 405 nm wavelengths [20].

Quantitative reverse transcription-polymerase chain reaction analysis (Q-PCR)

Total RNA was extracted using RNAeasy Plus Mini Kit. By the use of a poly T-tail primer

included in the one-step RT-PCR Kit, total RNA ($\leq 1 \mu\text{g}$) was reverse transcribed; cDNA was amplified according to the manufacturer's instructions.

By the use of QuantiTect Reverse Transcription Kit, the first-strand cDNA was synthesized; cDNA copies were counted by the absorbance at 260 nm. Aliquots of the cDNA were combined with the QuantiFast® SYBER® Green PCR Master Mix from Qiagen and primers and assayed in triplicate using a Rotor-Gene 6000 real-time RT-PCR.

According to the reported mouse cDNA sequences, the primers were synthesized in the National Center for Biotechnology Information data bank and their characteristics are shown in Table 1.

The comparative $2^{-\Delta\Delta C_T}$ method to analyze fold differences was used. Quantitative values were obtained from the threshold cycle (CT) number. The CT values from samples were plotted on the standard curve and the copy numbers were calculated with GAPDH as the internal control [21].

Statistical analysis

One-way ANOVA followed by Tukey's test was applied for multiple group comparisons of quantitative data. Qualitative parameters were assessed by the chi-square test. Also, $p < 0.05$ was considered significant. Data were analyzed using SPSS software (version 16) and presented as Mean \pm SEM (standard errors of the mean).

Results and Discussion

The major side effects of chemotherapeutic agents such as doxorubicin are due to the lack of tumor specificity which affects normal tissues and might induce unwanted effects such as male infertility [8]. On the other hand, it has been reported that honeybee products have positive effects on the reproductive performance of mammals [22]. In the present study, our findings revealed that exposure of mice to doxorubicin resulted in abnormalities in the histological and functional characteristics of testicular tissue and testicular weight, while royal jelly co-administration ameliorates the reproductive potential in doxorubicin -exposed male mice.

There were significant reductions in testis weight of the doxorubicin group ($p < 0.01$) and RJ2 + DOX groups ($p < 0.05$) in comparison with the sham, control, and RJs groups.

Table 1. Primer information for real-time PCR to study the effect of doxorubicin and royal jelly on apoptosis gene expression in testis of mice

Primer	Sequence
GAPDH	Forward: 5'-TGCACCACCAACTGCTTAG-3' Backward: 5'-GGATGCAGGGATGATGTTC-3'
P53	Forward: 5'-TGCACCACCAACTGCTTAG-3' Backward: 5'-GGATGCAGGGATGATGTTC-3'
Bax	Forward: 5'-CGGCGAATTGGAGATGAACTG-3' Backward: 5'-GCAAAGTAGAAGAGGGCAACC-3'
Bcl-2	Forward: 5'-ACCGTCGTGACTTCGCAGAG-3' Backward: 5'-GGTGTGCAGATGCCGGTTC-3'
Caspase-3	Forward: 5'-ACTTCTCCAACATTCCTGG-3' Backward: 5'-ATTCT TCTGGAGGAGAGGAG-3'
Caspase-8	Forward: 5'-TCGTCTATGGAACGGATGGG-3' Backward: 5'-ATCTC GGTAGGAAACGCAGT-3'

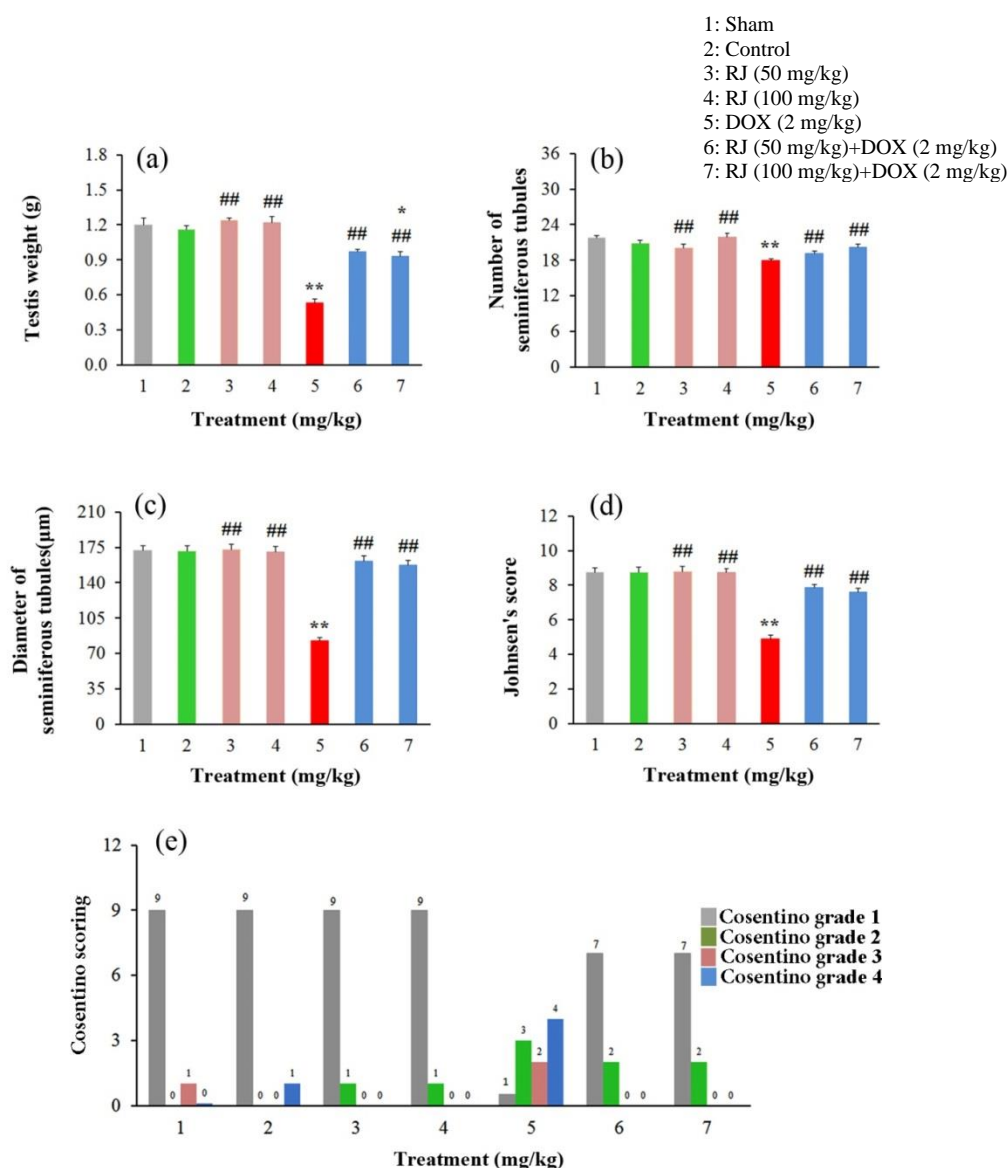


Figure 1. The effect of royal jelly and doxorubicin administration on testis weight and histological parameters (quantitative and qualitative) in mice; RJ: royal jelly; DOX: doxorubicin; 1: sham; 2: control; 3: RJ at a dose of 50 mg/kg, 4: RJ at a dose of 100 mg/kg, 5: DOX at a dose of 2 mg/kg, 6: RJ (50 mg/kg) + DOX (2 mg/kg), 7: RJ (100 mg/kg) + DOX (2 mg/kg); **p<0.01, *p<0.05 in comparison with the sham, and control groups, respectively; ##p<0.01 compared to the DOX group. The data are represented as Mean ± SEM. (a): testis weight; (b): number of seminiferous tubules; (c): diameter of seminiferous tubules; (d): Johnson's; (e): Cosentino scoring

A significant increase in this parameter was seen in royal jelly receiving groups compared to the doxorubicin group ($p < 0.01$). There was no significant difference in testicular weight both between RJs groups and between RJs + DOX groups ($p > 0.05$) (Figure 1a). Weight loss in doxorubicin -received mice could be explained by testicular parenchyma atrophy, reduced number of germ cells, decreased size of seminiferous tubules, and a lower rate of spermatogenesis. Moreover, induction of apoptosis, which leads to cell death, is another reason for testicular weight loss [23], as shown in this study.

Testis histological aspects showed remarkable seminiferous tubules shrinkages in the doxorubicin group as well as significant increases in inter-tubular spaces and a sharp decline in the population of interstitial cells. But, histological features between the sham, control, and royal

jelly groups were similar (Figure 2). Related data are demonstrated in Figures 1b-e, revealing a significant reduction in the diameter seminiferous tubules, Johnson's score, and Cosentino scoring of the doxorubicin group in comparison with the sham, control, and royal jelly groups ($p < 0.01$). Apoptosis in the tubules showed the toxicity of doxorubicin in testicular tissue, and testicular weight loss can be the cause of abnormalities in spermatogenesis and damage to seminiferous tubules as shown by Johnson's score, and Cosentino scoring. In this regard, we showed that testicular tissue degradation disrupted spermatogenesis by a significant reduction of sperm parameters in doxorubicin -treated mice, as previously reported [4,9]. Zanetti et al. showed that treatment with doxorubicin causes an important decrease in testicular weight resulting in reduction of spermatogenic cell number [8].

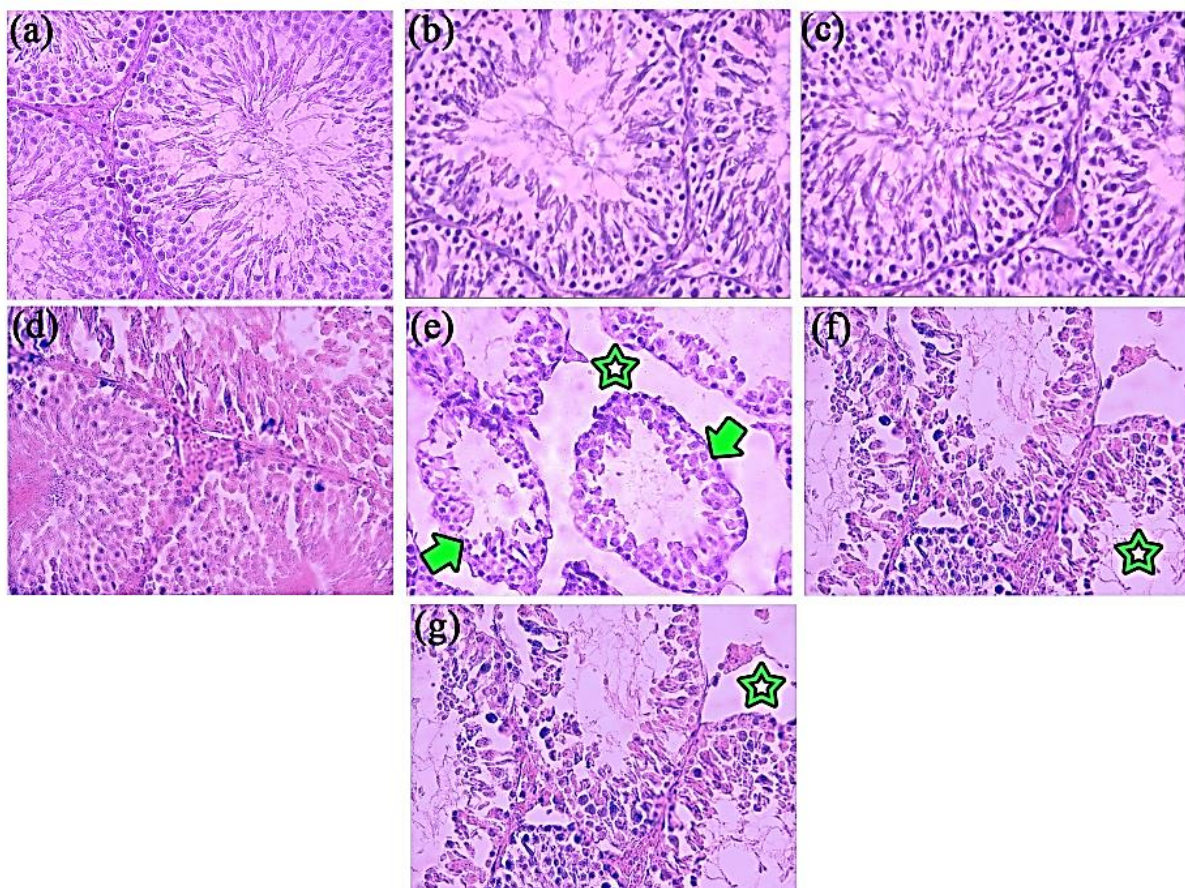


Figure 2. Histological characters of mice's seminiferous tubules cell in studied groups, stained by H&E dye ($\times 100$); (a): sham; (b): control; (c): RJ 1; (d): RJ 2; (e): DOX; (f): RJ 1 + DOX; (g): RJ 2 + DOX; RJ: royal jelly; DOX: doxorubicin ;the arrows refer to the low amount of sperms within seminiferous tubules and the stars show the absence of inter-tubular (interstitial) tissue.

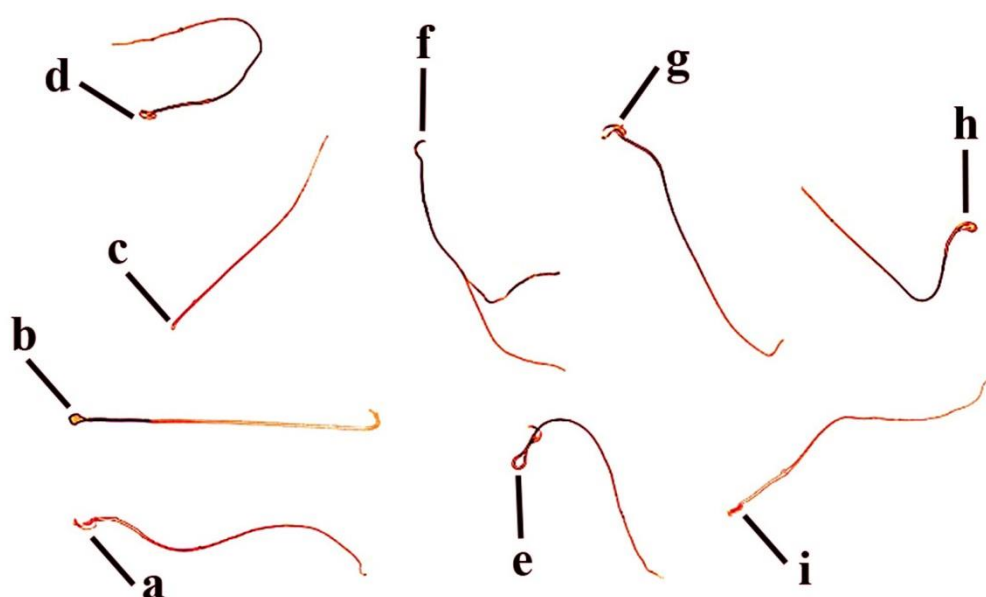


Figure 3. The spermatozoa's morphology and viability distinguished in the present study stained by H&E dye and photographed by a light microscope ($\times 200$). (a): normal and alive sperm; (b): amorphous head; (c): no head; (d): round head; (e): bent neck; (f): two tail; (g): two head; (h): bent head; (i): banana head; in b-i all the spermatozoa were dead; colorless spermatozoa are alive, while the dark red ones are dead spermatozoa.

Table 2. The quantitative estimation of sperm parameters after administration of royal jelly and doxorubicin on Balb/c mice

Groups	Sperm parameters			
	Count ($10^6/\text{mL}$)	Morphology (%)	Total motility (%)	Viability (%)
Sham	27.75 ± 0.23	67.62 ± 0.39	83.63 ± 0.45	85.25 ± 0.34
Control	27.62 ± 0.18	67.40 ± 0.43	84.42 ± 0.44	85.03 ± 0.45
RJ 1	$27.86 \pm 0.18^{\#\#}$	$67.58 \pm 0.25^{\#\#}$	$86.60 \pm 0.58^{\#\#}$	$88.15 \pm 0.34^{\#\#}$
RJ 2	$28.94 \pm 0.20^{\#\#}$	$68.01 \pm 0.31^{\#\#}$	$85.34 \pm 0.45^{\#\#}$	$86.01 \pm 0.40^{\#\#}$
DOX	$10.17 \pm 0.25^{**}$	$29.10 \pm 0.51^{**}$	$35.62 \pm 0.32^{**}$	$24.86 \pm 0.98^{**}$
RJ 1 + DOX	$22.34 \pm 0.56^{\#\#\#}$	$56.37 \pm 0.54^{\#\#\#}$	$79.15 \pm 0.79^{\#\#\#}$	$57.13 \pm 0.64^{\#\#\#}$
RJ 2 + DOX	$23.47 \pm 0.44^{\#\#\#}$	$59.36 \pm 0.50^{\#\#\#}$	$77.17 \pm 0.63^{\#\#\#}$	$56.03 \pm 0.50^{\#\#\#}$

The data are represented as Mean \pm SEM; RJ 1: royal Jelly at a dose of 50 mg/kg; RJ 2: royal Jelly at a dose of 100 mg/kg; DOX: doxorubicin; $^{**}p < 0.01$, $^*p < 0.05$ in comparison with the sham, and control groups, respectively; $^{\#\#\#}p < 0.01$ compared to the DOX group

Figure 3 displays the morphological features of spermatozoa containing defects in the viability, mid-piece, piece, and head. Spermatozoa parameters were significantly decreased in the doxorubicin and RJs + DOX groups than the sham, control, and royal jelly groups ($p < 0.01$). Treatment with royal jelly significantly increased the spermatozoa parameter compared to the doxorubicin group ($p < 0.01$). There were no significant differences in spermatozoa parameters between royal jelly groups as well as RJs + DOX groups ($p > 0.05$) (Table 2).

The MDA level of testis tissue revealed that there were significant increases in the doxorubicin ($p < 0.01$) and RJs+DOX ($p < 0.05$) groups compared to the sham, control, and royal jelly

groups. MDA level was significantly declined in royal jelly receiving groups compared to doxorubicin groups ($p < 0.01$). Additionally, there was no significant increase in the MDA level by the increasing dose among royal jelly receiving groups ($p < 0.05$) (Table 3). In contrast, there was a significant decrease in the TAC level in the doxorubicin group as well as RJs + DOX ($p < 0.05$) groups compared to the sham, control, and royal jelly groups ($p < 0.01$). In RJ 1, RJ 2, RJ 1 + DOX, and RJ 2+DOX groups, a significant increase in TAC levels was detected compared to the doxorubicin group ($p < 0.05$). There was no significant difference in the TAC level by the increasing dose between royal jelly receiving groups ($p < 0.05$) (Table 3). Although a number of

possible toxic mechanisms have been recognized for doxorubicin administration, the main harmful mechanism appears to be ROS generation. Increased levels of ROS can damage cellular components, lipids, proteins, and DNA, then resulting in cell death [24]. ROS overproduction

not only negatively affects fertilization potential but also causes spermatozoa damages through induction of sperm dysfunctions including motility, acrosomal reaction, and/or DNA integrity disruptions [25].

Table 3. Malondialdehyde (MDA), total antioxidant capacity (TAC), and apoptotic cells following administration of royal jelly and doxorubicin in Balb/c mice (n = 11)

Groups	Parameters		
	MDA (mmol/mL)	TAC (mmol/mL)	Levels of apoptotic cell (U/g) (%)
Sham	4.69 ± 0.07	0.94 ± 0.05	1.7 ± 0.08
Control	4.74 ± 0.08	0.93 ± 0.07	1.8 ± 0.10
RJ 1	4.65 ± 0.09 [#]	0.92 ± 0.06 [#]	1.6 ± 0.09 [#]
RJ 2	4.54 ± 0.10 [#]	1.05 ± 0.08 [#]	1.55 ± 0.08 [#]
DOX	27 ± 1.2 ^{**}	0.45 ± 0.03 ^{**}	29.8 ± 0.51 ^{**}
RJ 1 + DOX	7.26 ± 0.09 ^{###}	0.75 ± 0.05 ^{###}	2.5 ± 0.12 ^{###}
RJ 2 + DOX	7.71 ± 0.07 ^{###}	0.70 ± 0.06 ^{###}	2.9 ± 0.10 ^{###}

The data are represented as Mean ± SEM; RJ 1: royal Jelly at a dose of 50 mg/kg; RJ 2: royal Jelly at a dose of 100 mg/kg; DOX: doxorubicin; ^{**}p<0.01, ^{*}p<0.05 in comparison with the sham, and control groups, respectively; ^{###}p<0.01 compared to the DOX group

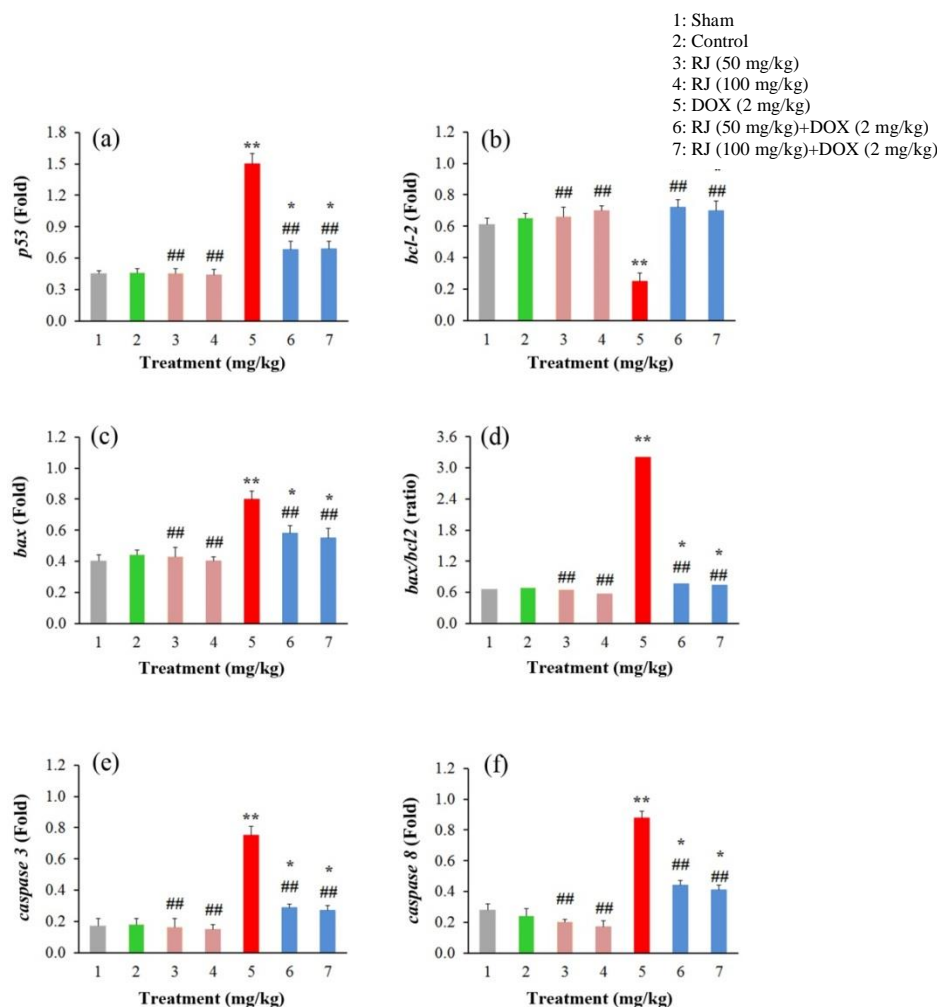


Figure 4. Expression of related genes of apoptosis in testis of Balb/c mice treated with royal jelly and doxorubicin using RT-PCR in 7 experimental groups; RJ: royal Jelly; DOX: doxorubicin; 1: sham; 2: control; 3: RJ at a dose of 50 mg/kg; 4: RJ at a dose of 100 mg/kg; 5: DOX at a dose of 2 mg/kg; 6: RJ (50 mg/kg) + DOX (2 mg/kg); 7: RJ (100 mg/kg) + DOX (2 mg/kg); ^{**}p<0.01, ^{*}p<0.05 in comparison with the sham, and control groups, respectively; ^{###}p<0.01 compared to the DOX group. The data are represented as Mean ± SEM. (a): p53; (b): bcl-2; (c): bax; (d): bax/bcl2; (e): caspase3; (f): caspase 8

The chemical structure of doxorubicin reasons the free radical generation followed by induction of oxidative stress and cellular injury, and also increasing the MDA level in testicular tissue [10]. The decreased TAC level explains this oxidative stress by Ibrahim and his colleagues [26]. The higher level of MDA in the doxorubicin group indicates testicular lipid peroxidation in another cause of testicular damage.

On the other hand, histological alternations including atrophy, detachment of germ cells, and other criteria such as improving sperm parameters, decreasing apoptosis and MDA, and increasing TAC in testis confirm the recovery of the reproductive parameters in doxorubicin-exposed mice treated by royal jelly, which could be ascribed to its antioxidant activities. The study by Elnagar showed the positive effects of royal jelly on the physiological status and a series of sperm parameters on heat-stressed male rabbits [27]. Mahdavi et al. revealed that royal jelly co-administration ameliorated the reproductive potential in heat stress-exposed male rats. Royal jelly co-administration improved sperm characteristics and early embryo development as well as sperm MDA level [28]. Moreover, royal jelly has the ability to diminish lipid peroxidation and elevate the antioxidant capacity of the testicular tissue [15].

According to Table 3, the evaluation of apoptotic cells showed a significant increase in the doxorubicin group than compared to the sham, control, and royal jelly groups ($p < 0.01$); at the same time, significant statistical increase was detected between RJs + DOX and sham, control, and royal jelly groups ($p > 0.05$). With raising the dose, there was no significant decrement in the apoptotic cells between royal jelly groups as well as RJs + DOX groups ($p < 0.05$). Apoptotic cells were significantly decreased in royal jelly receiving groups compare to the doxorubicin group ($p < 0.01$). The apoptotic genes expression is shown in Figure 4. In doxorubicin group, a significant decrease in bcl-2 expression was found in comparison with the sham, control, and royal jelly groups. While the expression levels of other genes significantly increased ($p < 0.01$). The expression levels of the p53, bax, caspase 3 and caspase 8 gene in RJs + DOX groups were significantly higher than the sham, control, and royal jelly groups ($p < 0.05$). There were no significant differences in the administration of apoptotic gene expression among royal jelly

receiving mice. Administration of RJ significantly increased the expression of bcl-2 and decreased expression levels of others compared to the doxorubicin group ($p < 0.01$).

The present study in line with other studies shows the role of p53, bax, and caspase-3 and -8 genes in doxorubicin -induced apoptosis in the testicular tissue [10]. This effect of doxorubicin occurs due to the DNA damage and subsequent p53 expression which in turn inhibits the activity of topoisomerase II, the enzyme responsible for DNA replication. Regulation of bax/bcl-2 ratio that promotes caspase endonucleases is another apoptosis pathway regulated by doxorubicin action in the testis. These apoptotic cascades prevent the division of spermatogonia cells and consequently impaired spermatogenesis [3]. A significant reduction in apoptosis by regulating gene-related cascade in doxorubicin co-administrated with doxorubicin were found that indicates the protective effects of RJ against doxorubicin are derived from its ability to improve the antioxidant status and prevent the mitochondria-dependent apoptosis pathway. Similar to our observations, it has been shown that royal jelly effectively protects the testicular tissue against nicotine-induced damages by antioxidant and anti-apoptotic effects [29]. It has been reported that royal jelly can effectively ameliorate heat stress-induced testiculopathies in rats through restoration of testicular antioxidant defense system as well as regulation of germ cells apoptosis [30].

By this therapeutic strategy of royal jelly, improvement of the efficacy of routine anticancer drugs, and also moderating their side effects on normal tissues could be possible. However, more studies about angiogenesis and autophagy death are suggested.

Conclusion

The present study showed that royal jelly had an ameliorative effect on the cellular toxicity induced by doxorubicin (an anticancer drug). This is possibly due to the antioxidant capacity of royal jelly. This study suggests the inclusion of royal jelly in the diet of patients who have to use doxorubicin may ameliorate reproductive disorders.

Acknowledgements

The authors express their gratitude to the Research Deputy of Kermanshah University of

Medical Sciences for the financial support of this research project [Grant NO: 97496].

Author contributions

Mansour Safaei Pourzamani was involved in performed the experiments, data analysis, and prepared the original draft of the manuscript; Shahrbanoo Oryan and Parichehr Yaghmaei contributed in conceptualization, and editing of the manuscript; Cyrus Jalili contributed to conceptualization, final editing, responding to reviewers and funding acquisition; Ali Ghanbari contributed in project administration, supervision, writing and editing of the manuscript, validation and funding acquisition. All authors read, critically reviewed, and approved the final manuscript.

Declaration of interest

The authors declare that there is no conflict of interest. The authors alone are responsible for the accuracy and integrity of the paper content.

References

- [1] Ahmed F, Urooj A, Karim AA. Protective effects of *Ficus racemosa* stem bark against doxorubicin-induced renal and testicular toxicity. *Pharmacogn Mag.* 2013; 9(34): 130–134.
- [2] Kunle-Alabi OT, Akindele OO, Raji Y. Coconut water improves testicular oxidative status in doxorubicin-treated male Wistar rats. *Afr J Med Med Sci.* 2021; 50(1): 19–30.
- [3] Hou MI, Chrysis D, Nurmio M, Parvinen M, Eksborg S, Soder O, Jahnukainen K. Doxorubicin induces apoptosis in germ line stem cells in the immature rat testis and amifostine cannot protect against this cytotoxicity. *Cancer Res.* 2005; 65(21): 9999–10005.
- [4] Yeh YC, Lai HC, Ting CT, Lee WL, Wang LC, Wang KY, Lai HC, Liu TJ. Protection by doxycycline against doxorubicin-induced oxidative stress and apoptosis in mouse testes. *Biochem Pharmacol.* 2007; 74(7): 969–980.
- [5] Mohan UP, Tirupathi Pichiah PB, Iqbal ST, Arunachalam S. Mechanisms of doxorubicin-mediated reproductive toxicity—a review. *Reprod Toxicol.* 2021; 102: 80–89.
- [6] El-Agamy SE, Abdel-Aziz AK, Esmat A, Azab SS. Chemotherapy and cognition: comprehensive review on doxorubicin-induced chemobrain. *Cancer Chemother Pharmacol.* 2019; 84(1): 1–14.
- [7] Srdjenovic B, Milic-Torres V, Grujic N, Stankov K, Djordjevic A, Vasovic V. Antioxidant properties of fullereneol C₆₀(OH)₂₄ in rat kidneys, testes, and lungs treated with doxorubicin. *Toxicol Mech Methods.* 2010; 20(6): 298–305.
- [8] Zanetti SR, Maldonado EN, Aveldaño MI. Doxorubicin affects testicular lipids with long-chain (C₁₈-C₂₂) and very long-chain (C₂₄-C₃₂) polyunsaturated fatty acids. *Cancer Res.* 2007; 67(14): 6973–6980.
- [9] Ozturk E, Kaymak E, Akin AT, Karabulut DE, Ünsal HM, Yakan Bİ. Thymoquinone is a protective agent that reduces the negative effects of doxorubicin in rat testis. *Hum Exp Toxicol.* 2020; 39(10): 1364–1373.
- [10] Rizk SM, Zaki HF, Mina MA. Propolis attenuates doxorubicin-induced testicular toxicity in rats. *Food Chem Toxicol.* 2014; 67: 176–186.
- [11] Yarmohammadi F, Rezaee R, Karimi G. Natural compounds against doxorubicin-induced cardiotoxicity: a review on the involvement of Nrf2/ARE signaling pathway. *Phytother Res.* 2021; 35(3): 1163–1175.
- [12] Guo H, Saiga A, Sato M, Miyazawa I, Shibata M, Takahata Y, Morimatsu F. Royal jelly supplementation improves lipoprotein metabolism in humans. *J Nutr Sci Vitaminol.* 2007; 53(4): 345–348.
- [13] Ahmad S, Campos MG, Fratini F, Altaye SZ, Li J. New insights into the biological and pharmaceutical properties of royal jelly. *Int J Mol Sci.* 2020; 21(2): 1–26.
- [14] Shalizar Jalali A, Najafi G, Hosseinchi M, Sedighnia A. Royal jelly alleviates sperm toxicity and improves in vitro fertilization outcome in stanozolol-treated mice. *Iran J Reprod Med.* 2015; 13(1): 15–22.
- [15] Silici S, Ekmekcioglu O, Eraslan G, Demirtas A. Antioxidative effect of royal jelly in cisplatin-induced testes damage. *Urology.* 2009; 74(3): 545–551.
- [16] Ottewell PD, Monkkonen H, Jones M, Lefley DV, Coleman RE, Holen I. Antitumor effects of doxorubicin followed by zoledronic acid in a mouse model of breast cancer. *J Natl Cancer Inst.* 2008; 100(16): 1167–1178.
- [17] Shiravi A, Jalili C, Vaezi G, Ghanbari A, Alvani A. Acacetin attenuates renal damage-

- induced by ischemia-reperfusion with declining apoptosis and oxidative stress in mice. *Int J Prev Med.* 2020; 11: 1–8.
- [18] Chehrei S, Moradi M, Ghiabi HR, Falahi M, Kaviani S, Ghanbari A. Pentoxifylline besides naltrexone recovers morphine-induced inflammation in male reproductive system of rats by regulating Toll-like receptor pathway. *Andrologia.* 2017; 49(9): 1–9.
- [19] Feyli SA, Ghanbari A, Keshtmand Z. Therapeutic effect of pentoxifylline on reproductive parameters in diabetic male mice. *Andrologia.* 2017; 49(1): 1–7.
- [20] Wang S, Xie T, Sun S, Wang K, Liu B, Wu X, Ding W. Liu B, Wu X, Ding W. DNase-1 treatment exerts protective effects in a rat model of intestinal ischemia-reperfusion injury. *Sci Rep.* 2018; 8(1): 1–9.
- [21] Darakhshan S, Ghanbari A. Tranilast enhances the anti-tumor effects of tamoxifen on human breast cancer cells in vitro. *J Biomed Sci.* 2013; 20(1): 1–13.
- [22] Hashem NM, Hassanein EM, Simal-Gandara J. Improving reproductive performance and health of mammals using honeybee products. *Antioxidants.* 2021; 10(3): 1–24.
- [23] Takahashi H, Tainaka H, Umezawa M, Takeda K, Tanaka H, Nishimune Y, Oshio S. Evaluation of testicular toxicology of doxorubicin based on microarray analysis of testicular specific gene expression. *J Toxicol Sci.* 2011; 36(5): 559–567.
- [24] Sena LA, Chandel NS. Physiological roles of mitochondrial reactive oxygen species. *Mol Cell.* 2012; 48(2): 158–167.
- [25] Moazamian R, Polhemus A, Connaughton H, Fraser B, Whiting S, Gharagozloo P, Aitken RJ. Oxidative stress and human spermatozoa: diagnostic and functional significance of aldehydes generated as a result of lipid peroxidation. *Mol Hum Reprod.* 2015; 21(6): 502–515.
- [26] Ibrahim RY, Mansour SM, Elkady WM. Phytochemical profile and protective effect of *Ocimum basilicum* aqueous extract in doxorubicin/irradiation-induced testicular injury. *J Pharm Pharmacol.* 2020; 72(1): 101–110.
- [27] Elnagar SA. Royal jelly counteracts bucks' "summer infertility". *Anim Reprod Sci.* 2010; 121(1-2): 174–180.
- [28] Mahdivand N, Najafi G, Nejati V, Shalizar-Jalali A, Rahmani F. Royal jelly protects male rats from heat stress-induced reproductive failure. *Andrologia.* 2019; 51(3): 13–18.
- [29] Azad F, Nejati V, Shalizar-Jalali A, Najafi G, Rahmani F. Antioxidant and anti-apoptotic effects of royal jelly against nicotine-induced testicular injury in mice. *Environ Toxicol.* 2019; 34(6): 708–718.
- [30] Mahdivand N, Shalizar-Jalali A, Nejati V, Najafi G, Rahmani F. Adaptogenic potential of royal jelly in reproductive system of heat stress-exposed male rats. *J Therm Biol.* 2021; 96: 1028–1027.

Abbreviations

DOX: doxorubicin; RJ: royal jelly; H&E: hematoxylin-eosin; MDA: malondialdehyde; TAC: total antioxidant capacity; TBA: tertiary-butyl alcohol; Q-PCR: quantitative reverse transcription–polymerase chain reaction analysis; JTBS: Johnson tubular biopsy score